Single center experience in Chiari I Decompression w/ woSyringomyelia performing Tonsillar Coagulation without Duraplasty

Departmen of Neurosurgery,
Brown University Department of Neurosurgery

Co-Authors

Dr. Heather Spader, Department of Neurosurgery

Dr. Jerry Boxerman, Diagnostic Imaging, Brown University

Dr. David Mandelbaum, Pediatric Neurology, Brown University

Dr. Craig Eberson, Orthopedic Surgery, Brown University

Dr. Jeff Rogg, Diagnostic Imaging, Brown University

BROWN

Objective

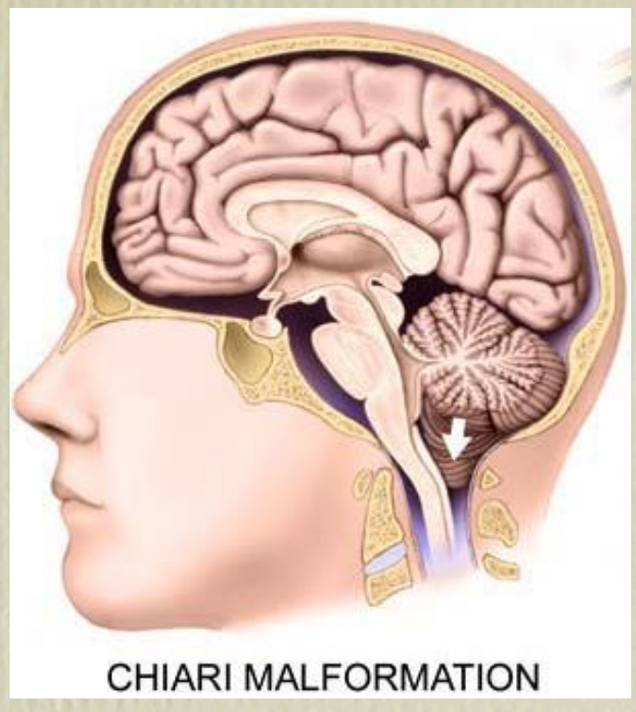

- **Pseudomeningocele**
- **Chemical Meningitis**
- **Cerebellar slump**

Report a single center experience in the treatment of Chiari I malformations with coagulation of cerebellar tonsils **without duraplasty**

Methods

- Chiari I Diagnosis
  - Interdisciplinary work-up for clinical criteria (Neurology&Neurosurgery)
  - Radiological criteria
    - Tonsillar ectopia (> 5mm)
    - +/- Syringomyelia
    - +/-Scoliosis
    - Positive cine flow studies (optional)

Methods: CINE FLOW

- All scans performed 1.5T
- Routine Sag T1, Ax T2 TSE, Ax T2Flash
- Sag Cine Phase Contrast:
  - TR/TE/Flip angle = 55/18/10
  - FOV 20, Matrix 256x192
  - 20 measures, retrospective gating
  - VENC 5

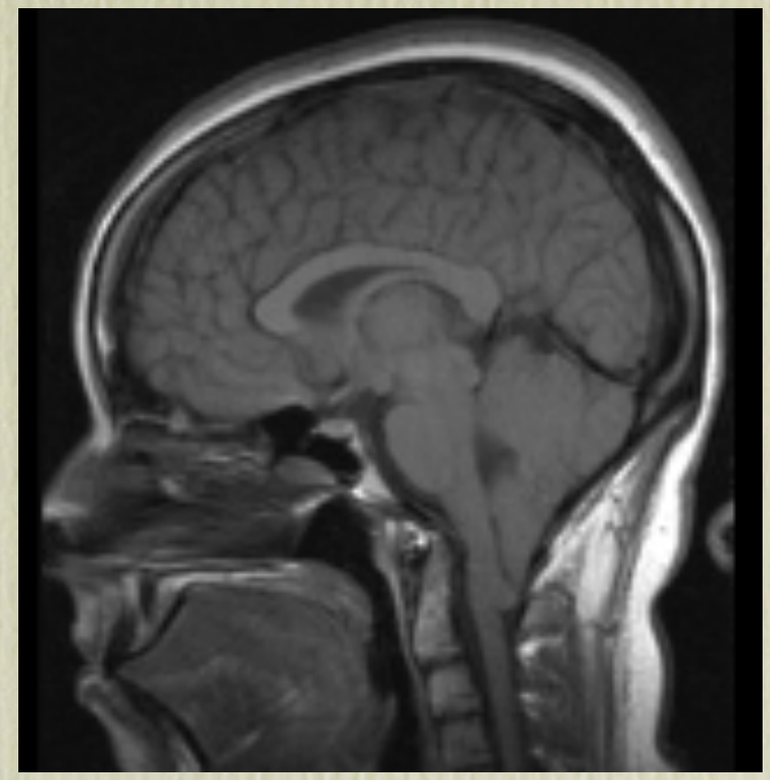



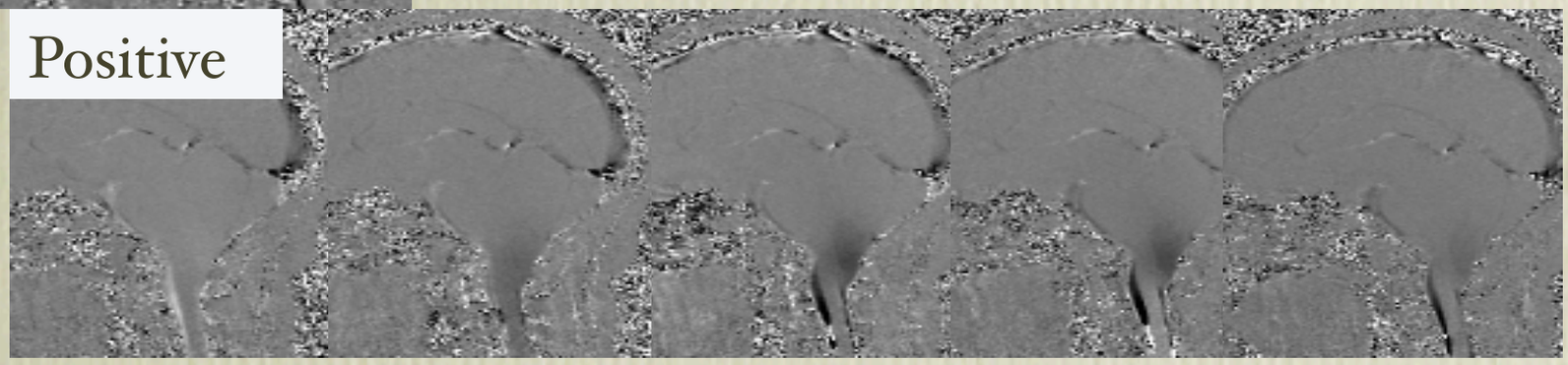

Surgical Technique I

- Posterior Fossa craniectomy to the level of the inferior nuchal line

- Wide lateral foramen magnum exposure to bilateral occipital condyles

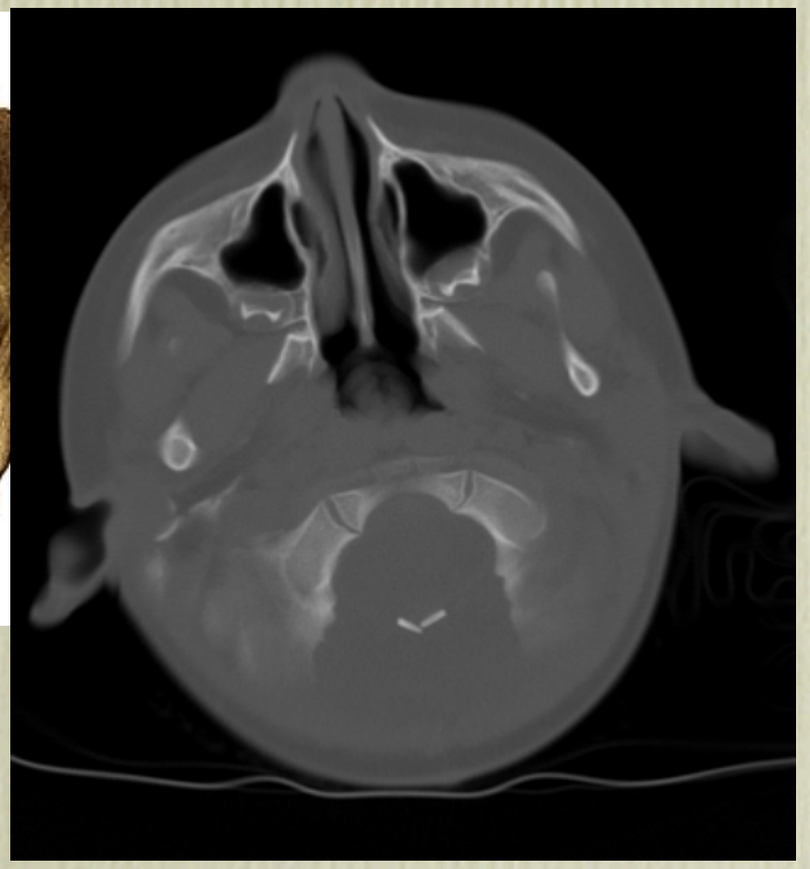

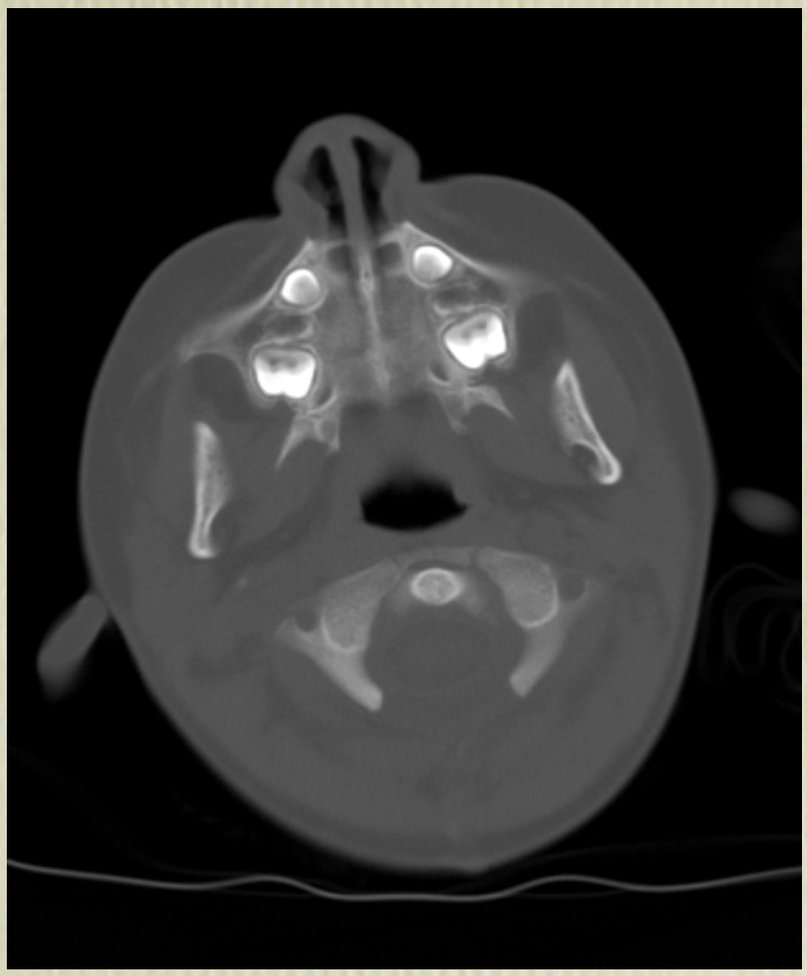

- C1 laminectomy to vertebral notch

BROWN

Surgical Technique

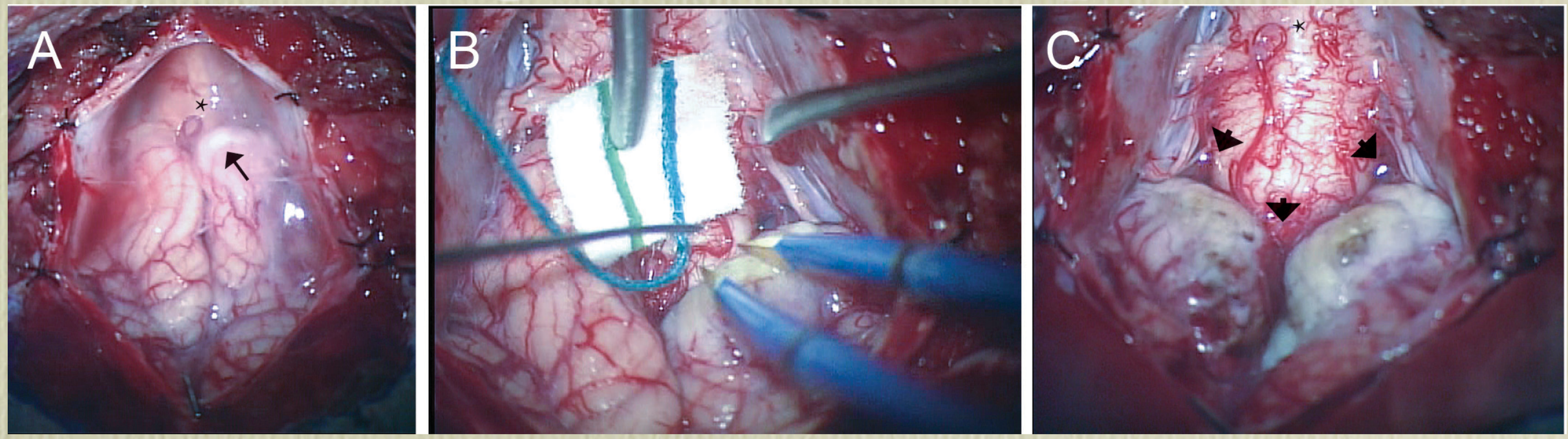

- Straight dural opening
- Ectopic cerebellar tonsils "reduced" with bipolar cautery
- Obex, 4th ventricle, choroid plexus, basolateral cisterns, intracranial vertebral arteries, exit of CN XI visualized
- Straight dural closure without dural grafting (running 5-0 prolene sutures)

Patient Information (2009-2011)

- 17 patients
- Average age: 19 (range: 3-41 years)
- Sex: 11 male, 6 female
- 7 patients with syringomyelia
- 2 patients with progressive scoliosis

BROWN

Follow-up

- Average length of follow-up: 9 months (range 3-24 months)
- MRI at 3 months and 1 year post surgery
- 15/17 patients had > 1 year follow-up

BROWN

Outcome

Patient	Age, Sex	Headaches	Syringomyelia	Headaches Post-op Improved	Other Symptoms Post-op Improved	Syringomyelia Post-op
1	15, M	Y	Y	Y	Y	Stable
2	21, M	Y	Y	Y	Y	Decreased
3	9, F	Y	N	Y	Y	-
4	16, M	Y	N	Y	Y	-
5	13, F	Y	N	Y	N/A	-
6	38, M	N	Y	N/A	Y	Decreased
7	15, F	Y	N	N	N	-
8	12, F	Y	Y	Y	Y	Stable
9	13, F	N	N	N/A	Y	-
10	13, F	Y	Y	Y	Y	Decreased
11	17, M	Y	Y	Y	Y	Decreased
12	2, M	Y	Y	Y	Y	Decreased
13	15, F	Y	N	N	N/A	-
14	15, F	Y	N	Y	Y	-
15	11, F	Y	N	-	-	-
16	3, M	Y	N	No f/u	No f/u	-
17	3, M	Y	N	No f/u	No f/u	-

Complications

- Low surgical/ perioperative morbidity
- One patient needed postoperative EVD for development of hydrocephalus and subsequent development of syrinx

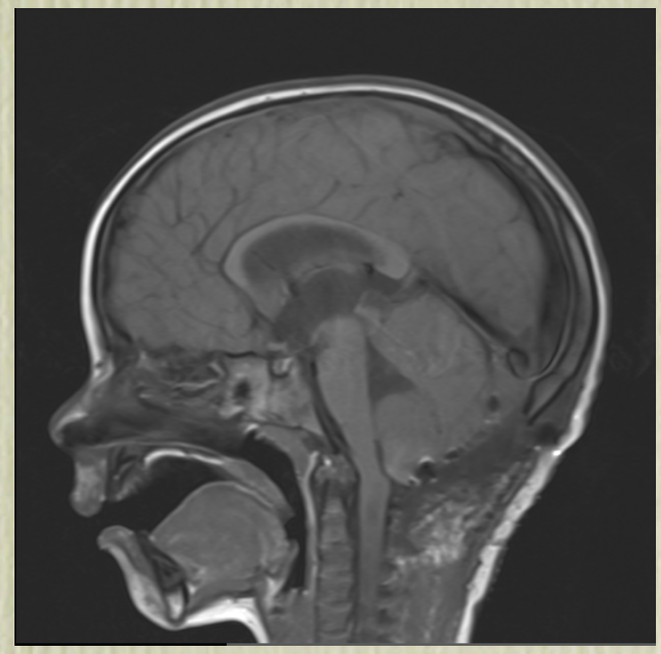

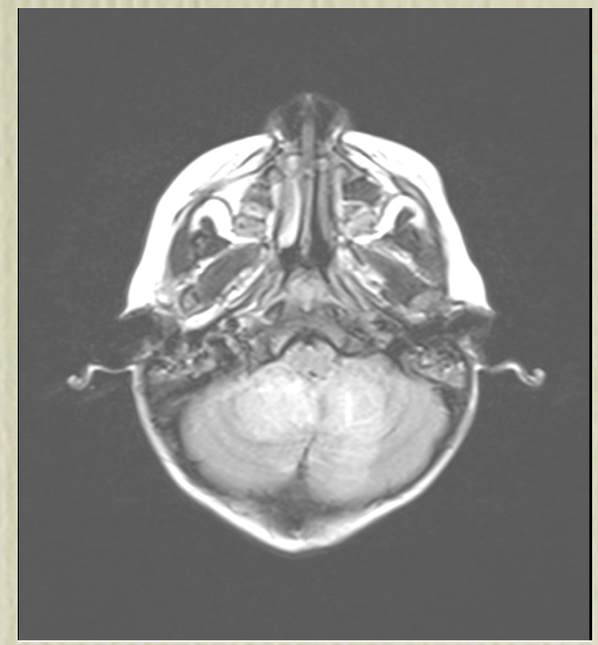

BROWN

Ilustrative case # 1 (2012)
30 year old female with Syringomyelia and Occipital headaches

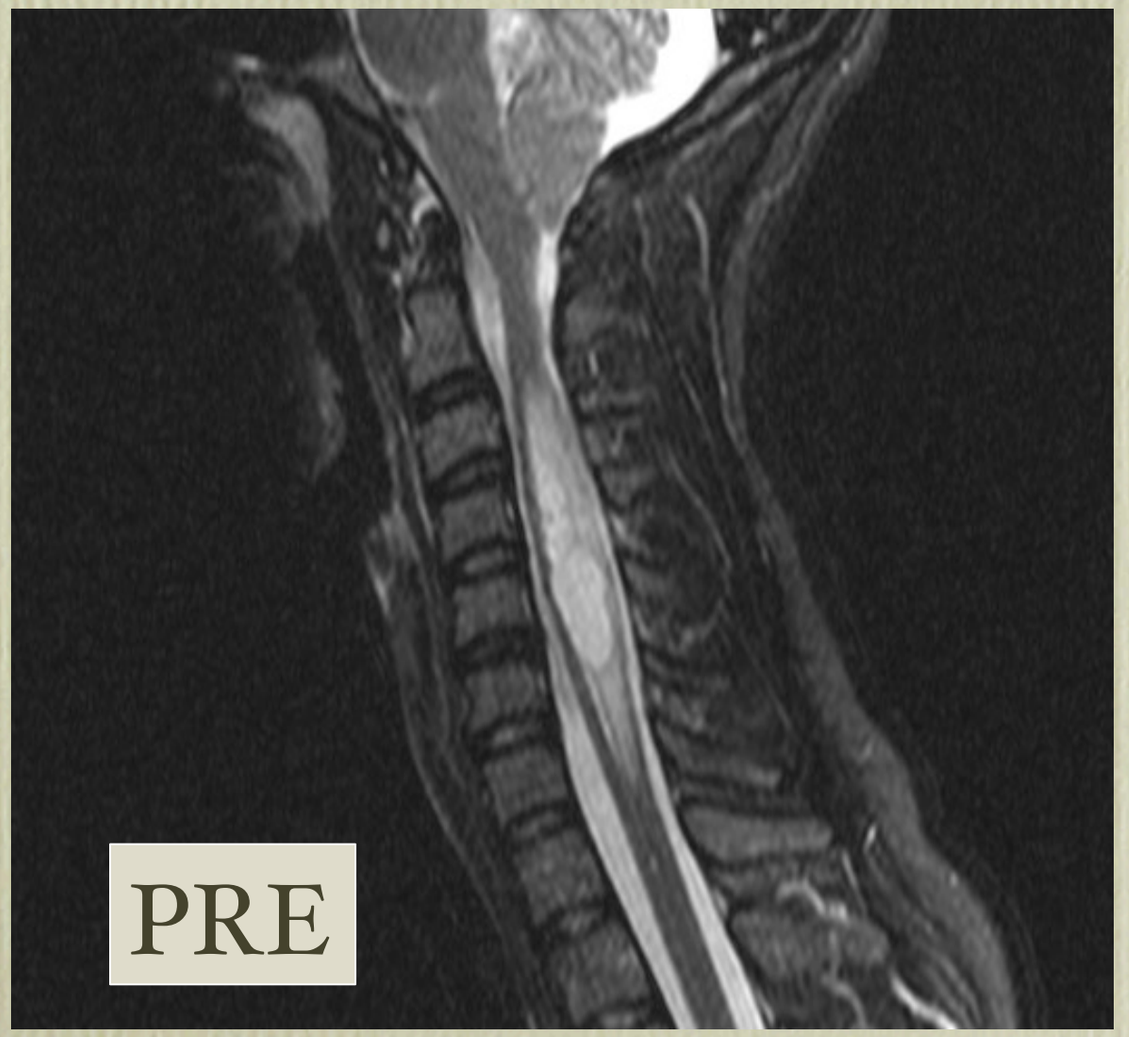

BROWN

Comparison (Discussion)

	Tubbs, et al 2011	Our Patients
Relief of Symptoms	83%	80%
Complications	2.4%	0.06%
Relief of Syrinx (after 1st Surgery)	80%	71%

Source: 1: Tubbs RS, Beckman J, Naftel RP, Chern JJ, Wellons JC 3rd, Rozzelle CJ, Blount JP, Oakes WJ.
Institutional experience with 500 cases of surgically treated pediatric Chiari malformation Type I. J Neurosurg Pediatr. 2011 Mar 7(3):248-56.

Conclusion

ANOTHER SINGLE CENTER EXPERIENCE

- First series reported of Chiari I decompression with straight dural opening, coagulation of tonsils and no duraplasty
- Similar clinical results to duraplasty but small numbers and longer follow-up needed
- Benefits

Less leaking complications (" no repair CSF leak")

No artificial graft

- Potential complications

Coagulation associated "thermal injury"

BROWN