Morphologies of Chiari I deformity: what matters

Charles Raybaud

Hospital for Sick Children, University of Toronto

charles.raybaud@sickkids.ca

Chiari: malformations or deformities?

- Definitions relate to pathogenesis, not degree
  - Malformation
    - Chiari III: NTD (cranio-cervical encephalocele)
  - Deformities
    - Chiari II: secondary to NTD (myelomeningocele)
    - Chiari I: other chronic causes
  - Herniation: acute/subacute mass effect
- What makes no sense in this perspective
  - tonsillar descent cut-off of 5mm
  - Chiari 0 and Chiari 1.5

Chiari 1 deformity: possible processes

- Small cranial container
  - suture synostosis, mainly Crouzon
  - intracranial hypotension with closed sutures, thick skull, thick dura
  - other etiologies of thick skull (e.g. thalassemia)
- Large cranial content: fore- and/or hind-brain
  - NF1
  - macrencephaly, hemimegalencephaly
  - cerebellar hyperplasia
  - chronic supratentorial mass effect (i.e chronic hydrocephalus)
- Small posterior fossa
  - synchondroses
  - CVJ malformations

Not a malformation but a deformity

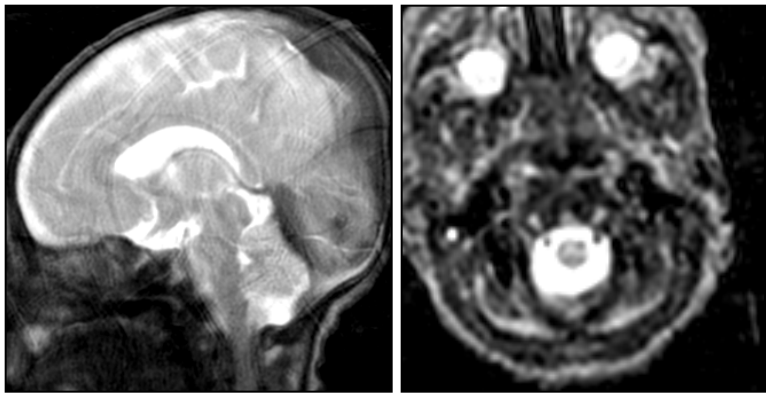

29w/9d

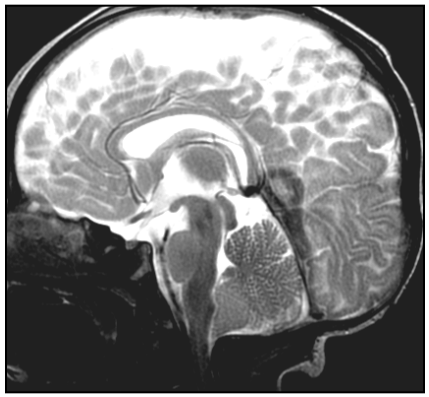

2m

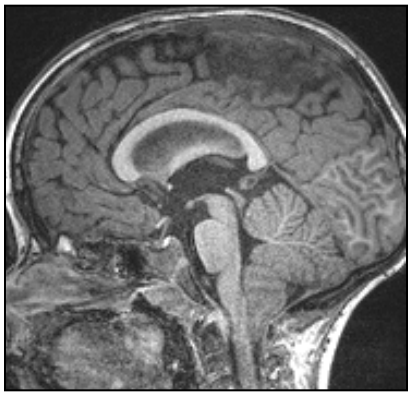

4y

4y

11y

Uncommonly, Chiari 1 deformity may be shown to appear or regress

Anatomical landmarks of posterior fossa

- Chamberlain, McGregor, McRae
- Wackenheim, clivo-cervical angle
- Osteo-neural landmarks
  - incisura → mid-midbrain
  - synchondrosis → mid-pons
  - basion → obex
  - dens → medulla/cord
- Patent cisterns
- Regular pentagon

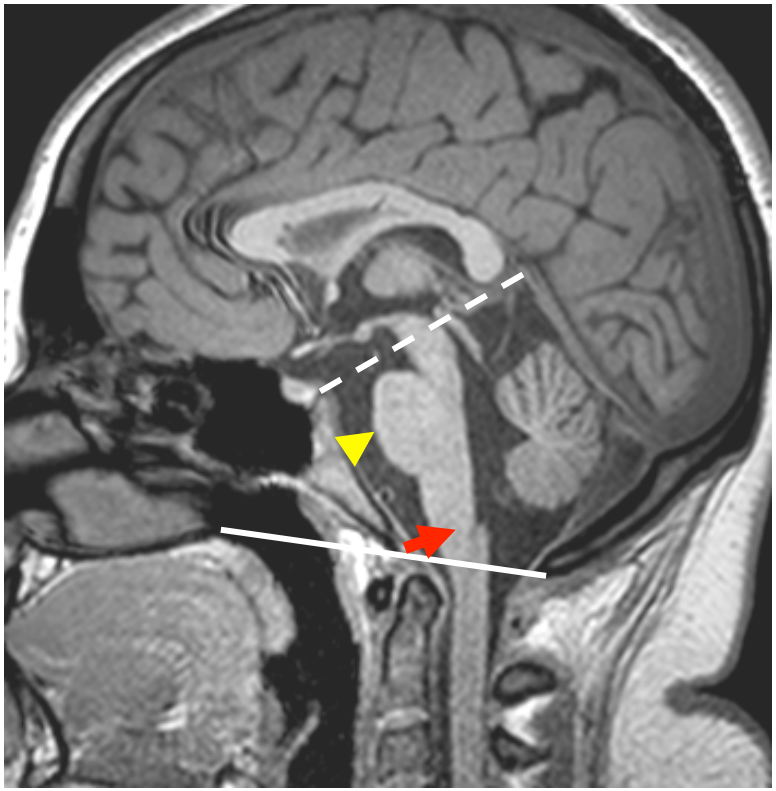

Anatomical landmarks of posterior fossa

- Chamberlain, McGregor, McRae
- Wackenheim, clivo-cervical angle
- Osteo-neural landmarks
  - incisura → mid-midbrain
  - synchondrosis → mid-pons
  - basion → obex
  - dens → medulla/cord
- Patent cisterns
- Regular pentagon

Common Chiari 1

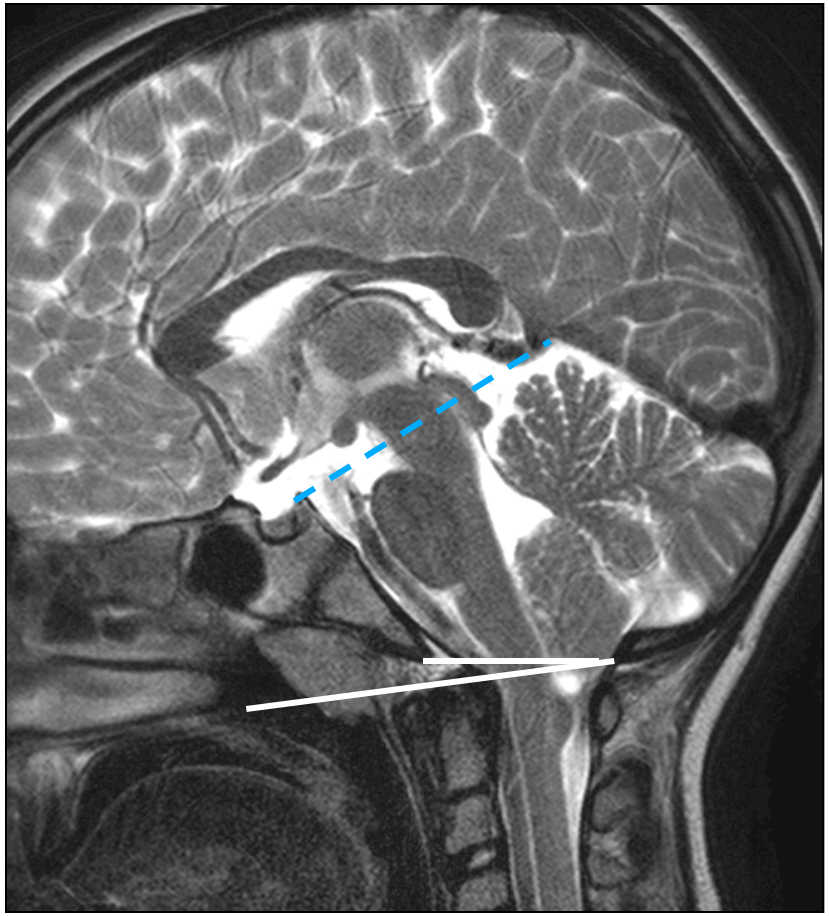

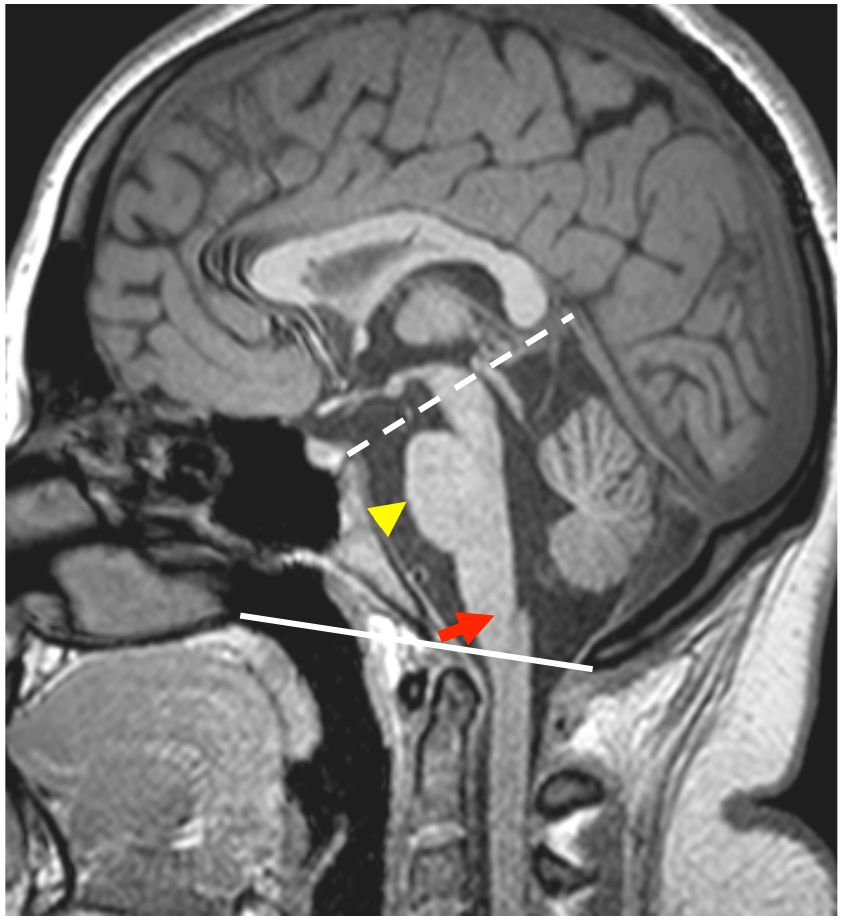

- flat posterior fossa, low hindbrain, effaced cisterns
- clivo-cervical angle normal, asymmetric pentagon

Small posterior fossa

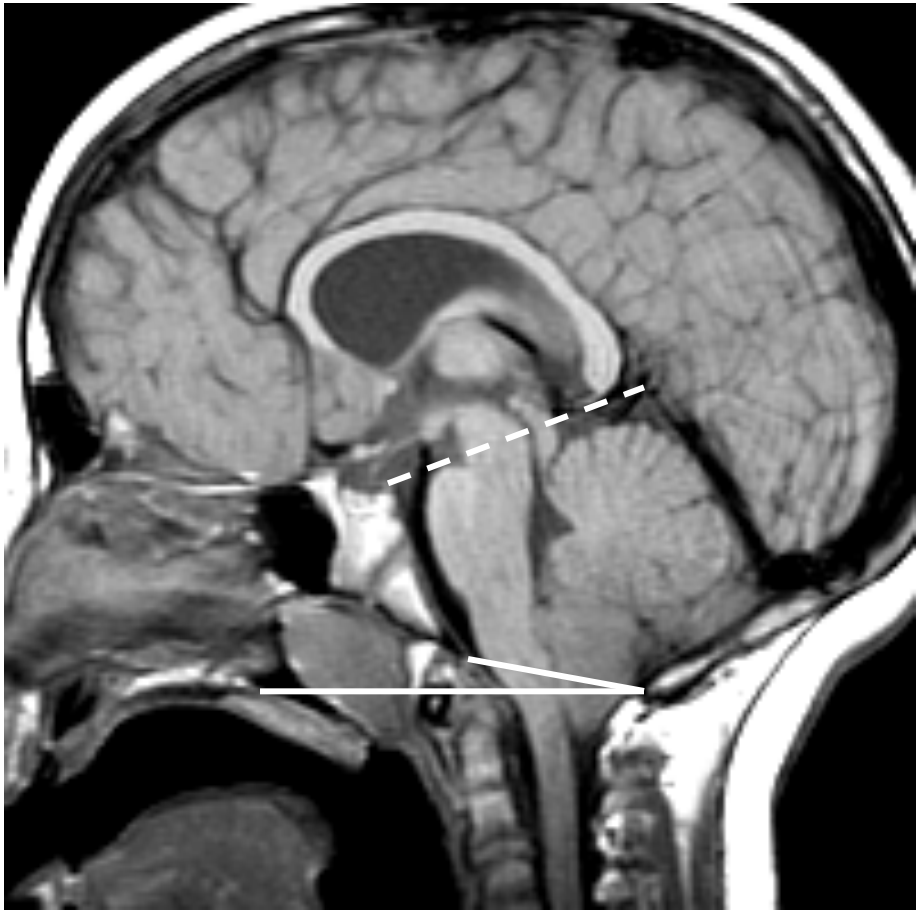

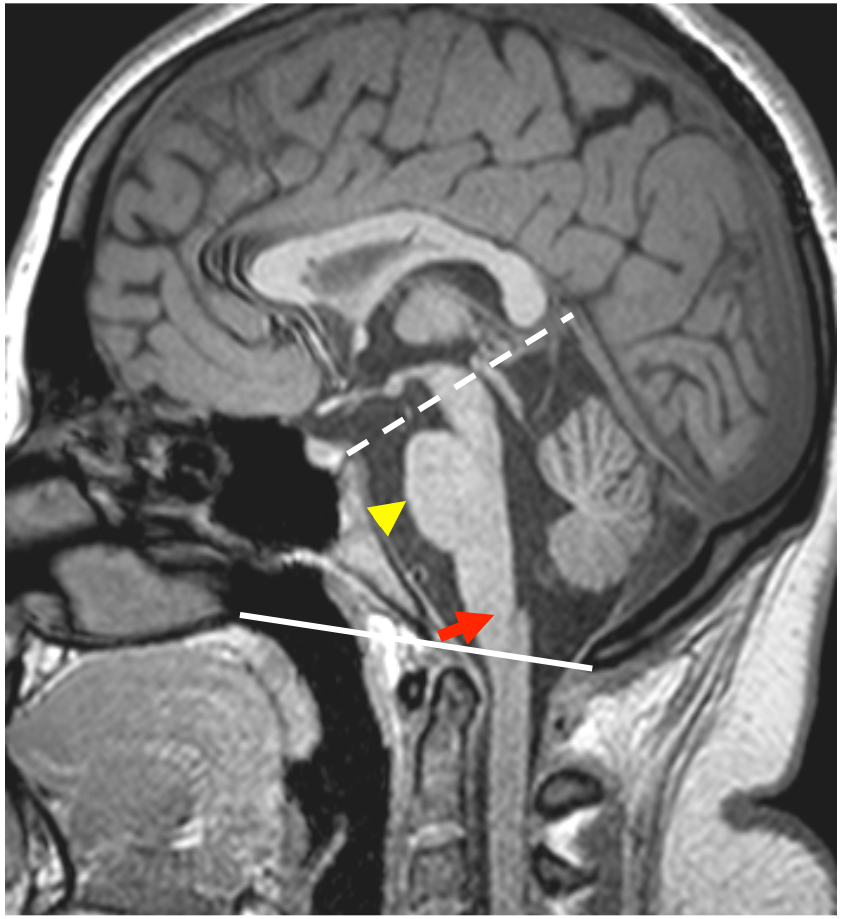

- short clivus, short supraoccipital, shallow PF with low & high hinbrain
- clivo-cervical angle normal, asymmetric pentagon

Small posterior fossa

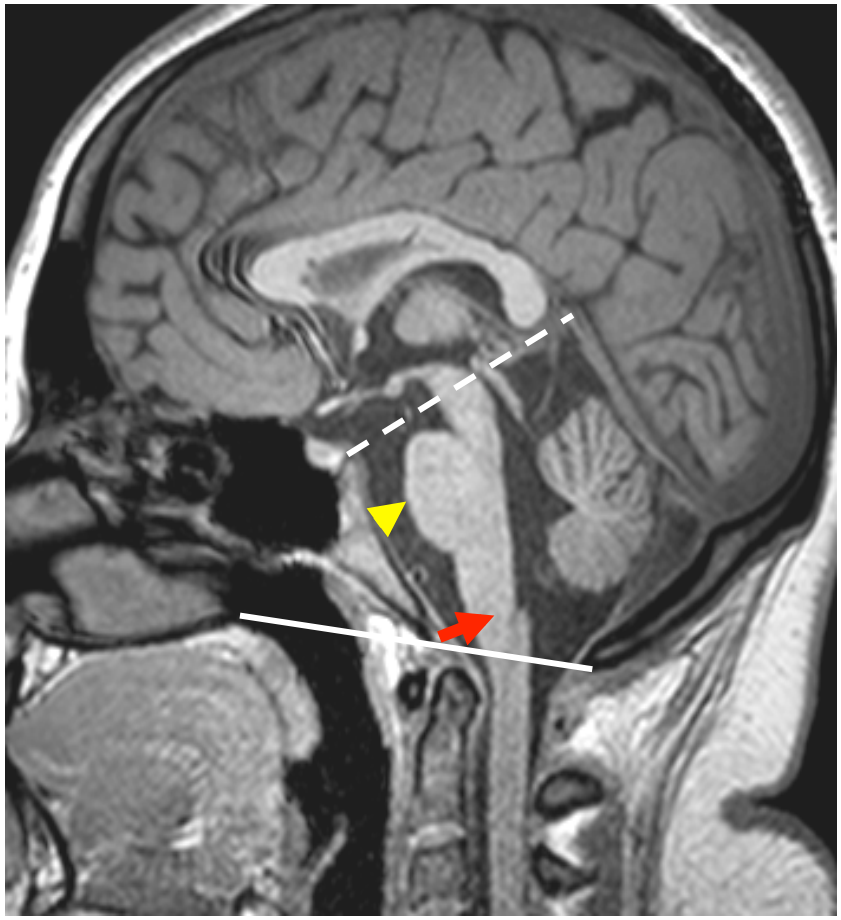

- small posterior fossa, effaced cisterns, Chiari I features
- the vaults gives way, cerebellar ascent, distorted pentagon

Small posterior fossa, retroverted dens

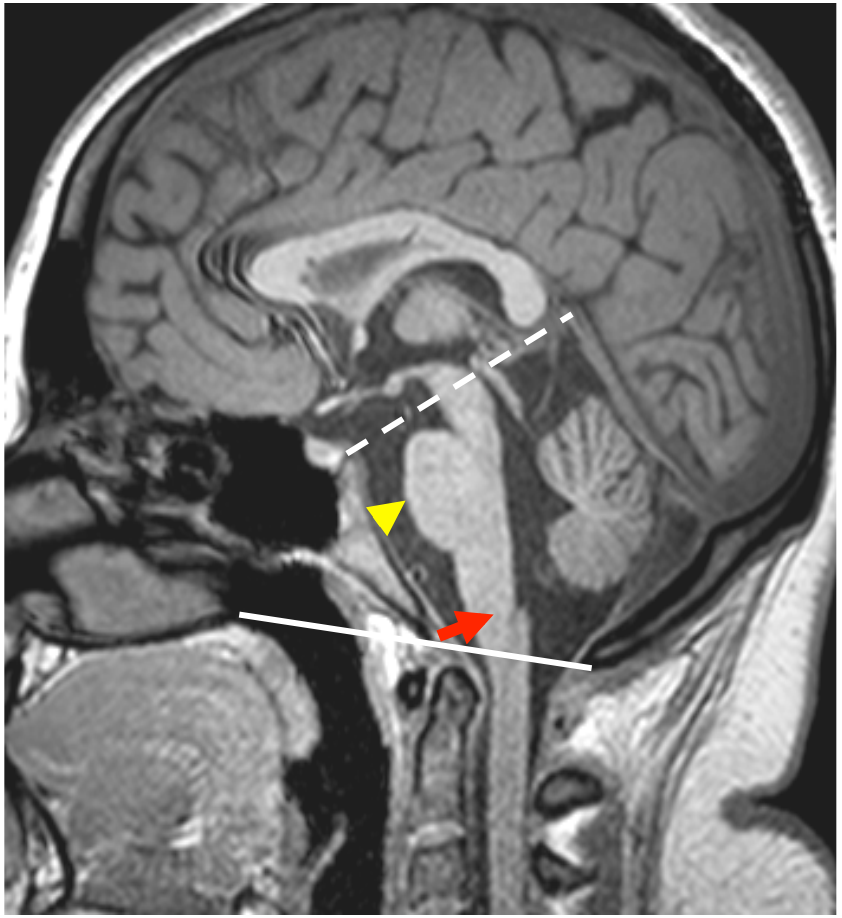

- short clivus, abnormal craniocervical angulation with long “retroverted” dens, basal invagination
- clivo-cervical angle decreased, flattened pentagon

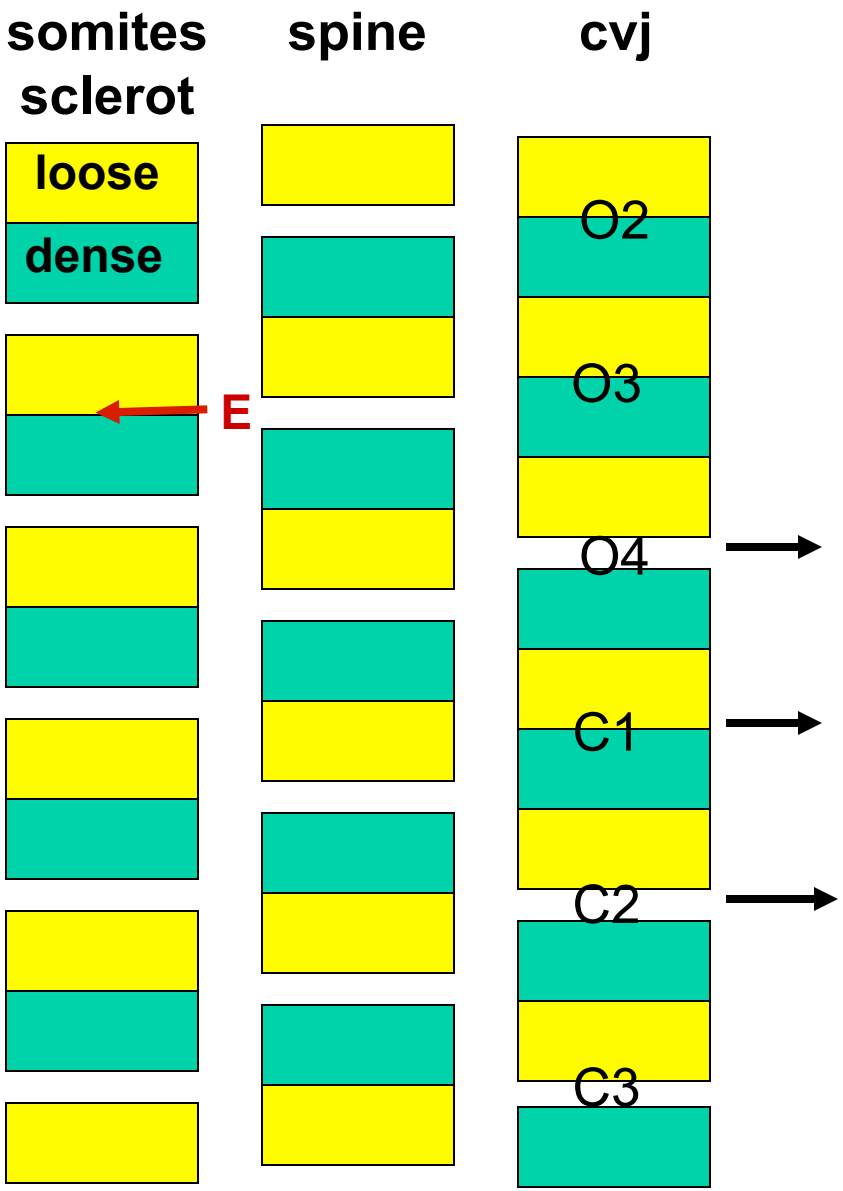

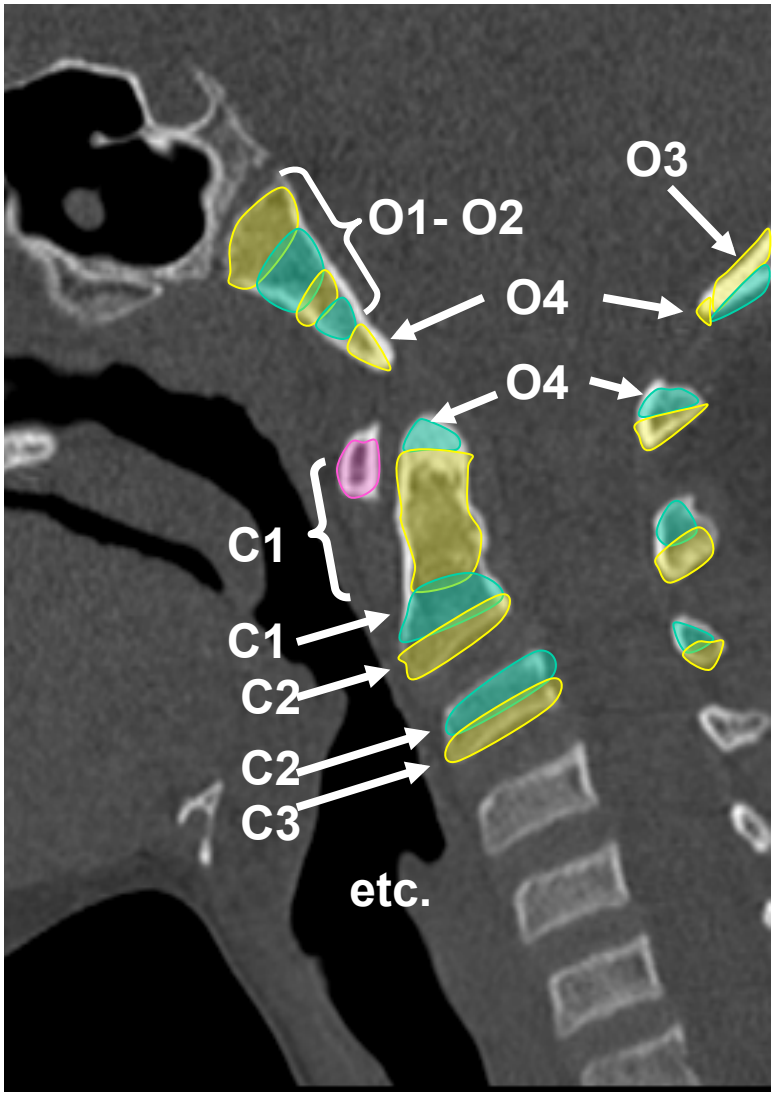

E: Ebner fissure

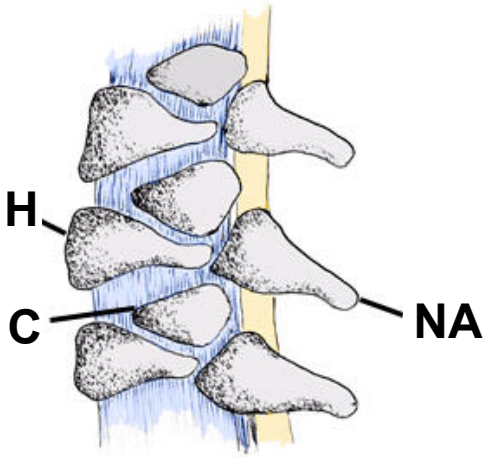

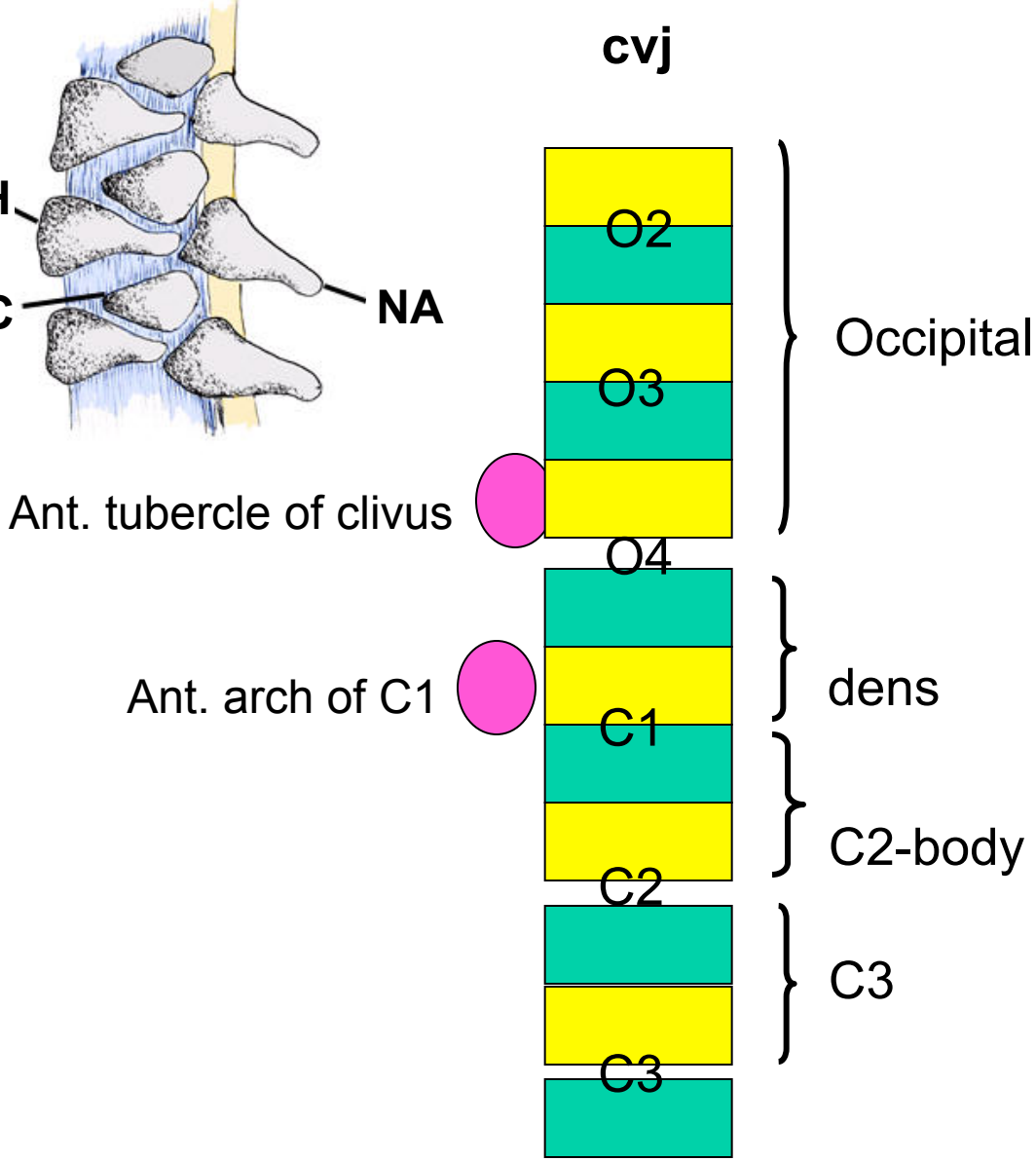

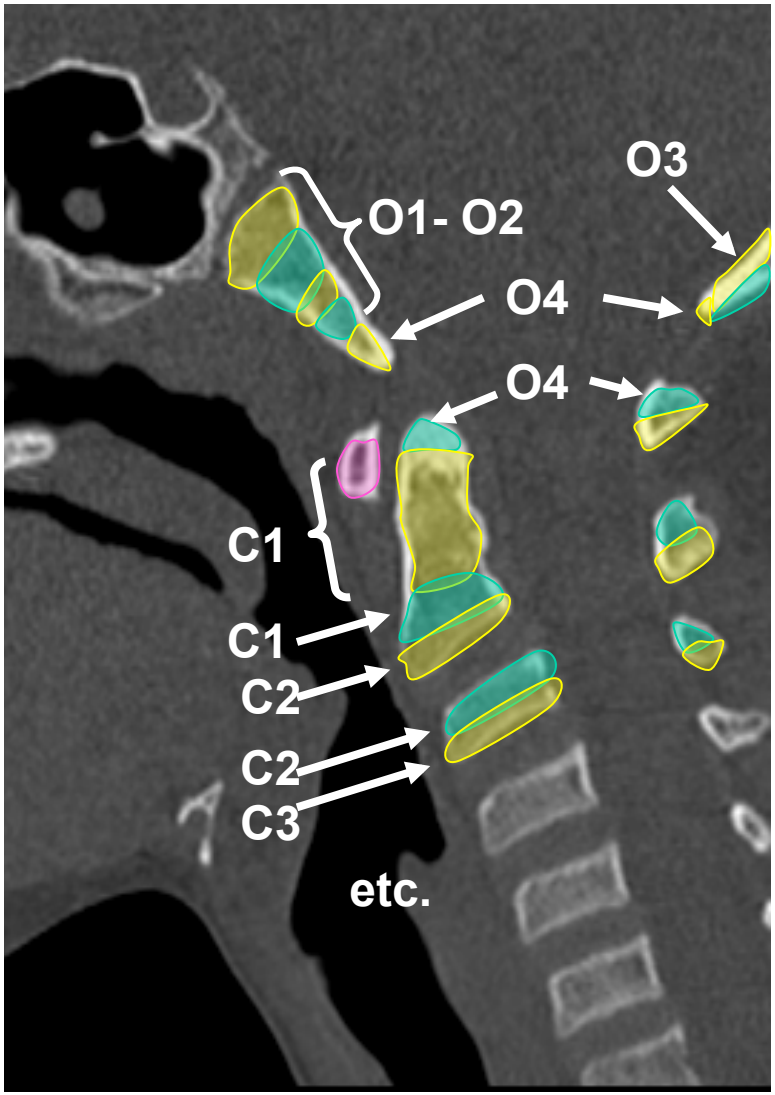

- Centrum intersegmental
- Hypocentrum segmental; lost except O4 and C1

Malformations or craniovertebral juction

- Aplasia
  - vs lack of ossification
- Hypoplasia
- Abnormal segmentation (homeobox)
  - cranial shift
  - caudal shift
  - mosaic
- For each:
  - centrum, hypocentrum, lateral
  - symmetric or not
  - single or in combination

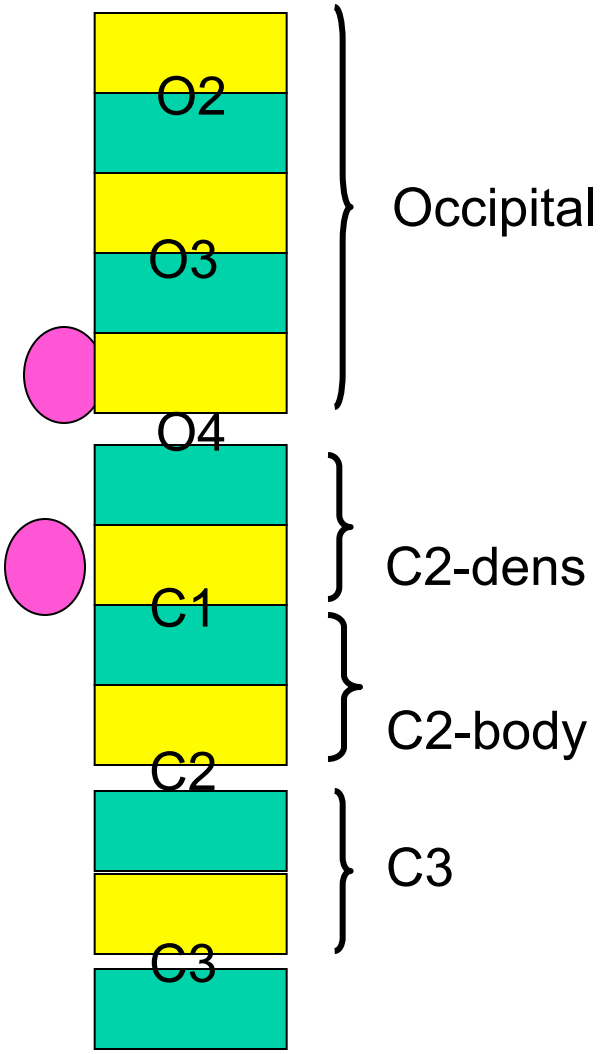

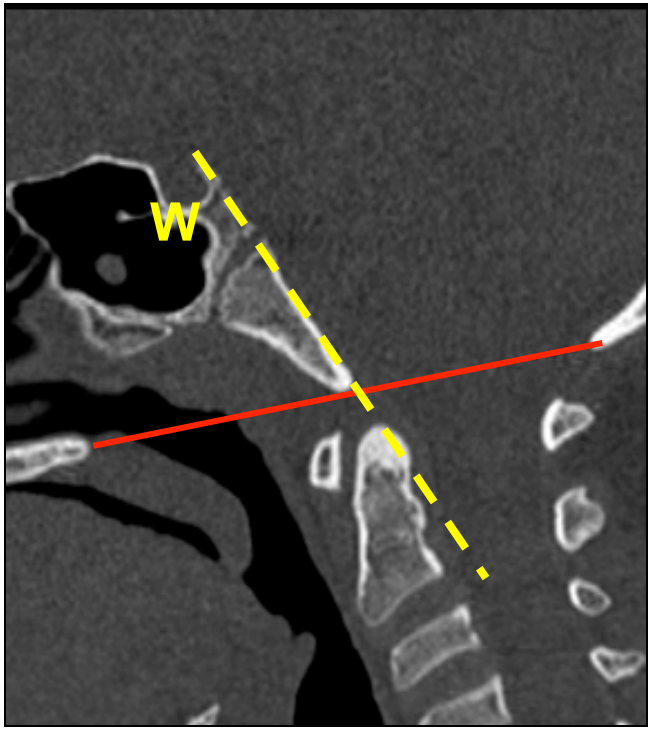

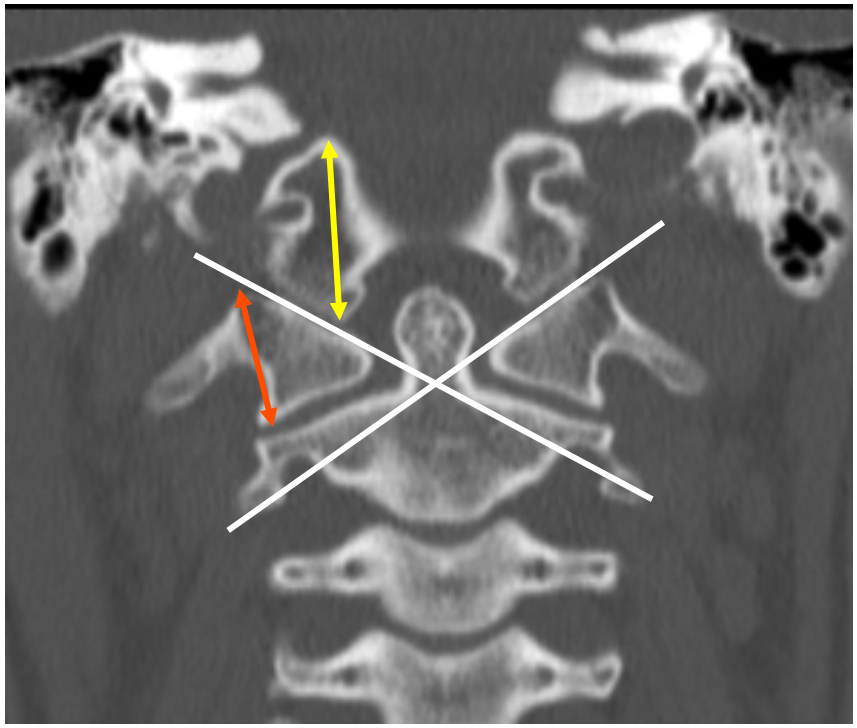

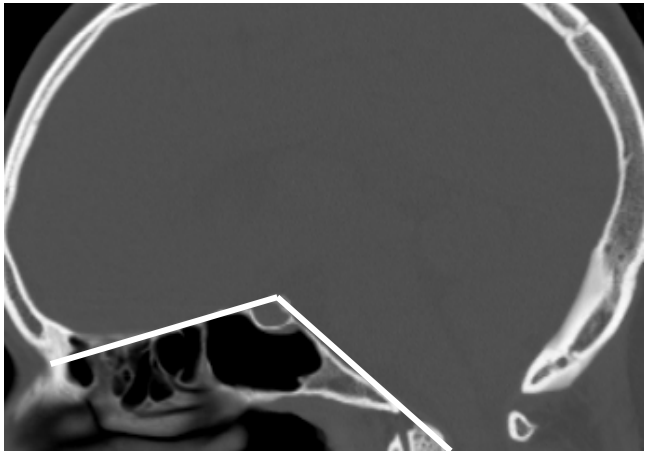

- cephalic flexion is at occipito-atlantal joint mostly
- Jugular tubercle + condyle: 25mm
- Lateral mass: 17mm
- pB-C2 < 9mm

Landmarks

Occipital hypoplasia and Chiari I

- Head flexed forward, basal invagination
- Relative ascent of the dens
- Main fulchrum for head flexion remains at occipito-atlantal joints, while dens part of fixed spine, brainstem part of moving head

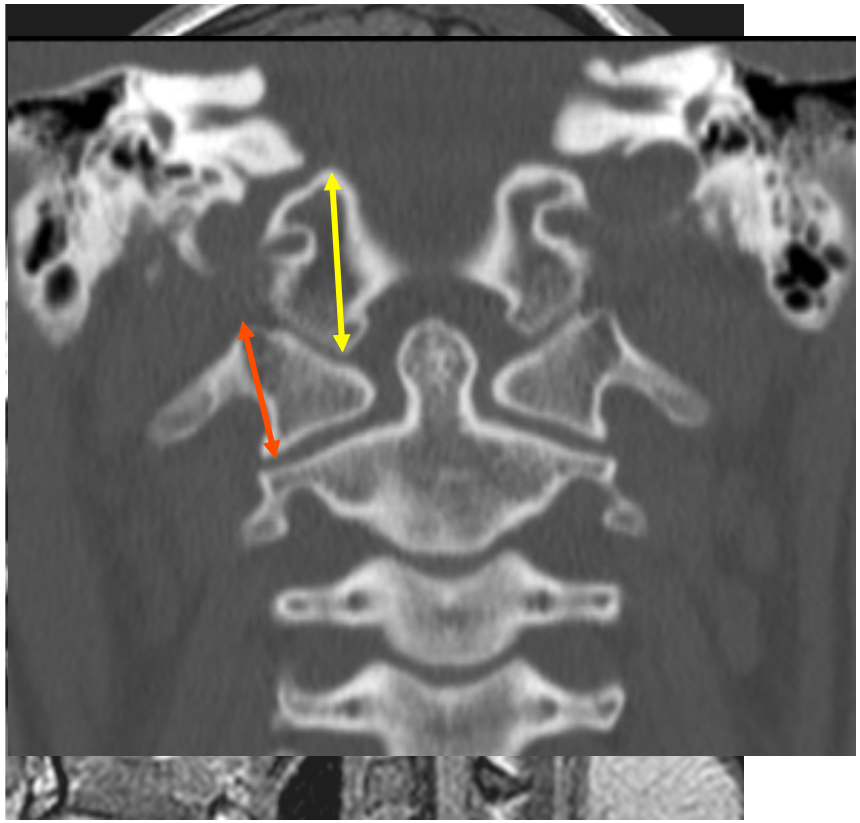

Cranial segmentation shift: cervicalization

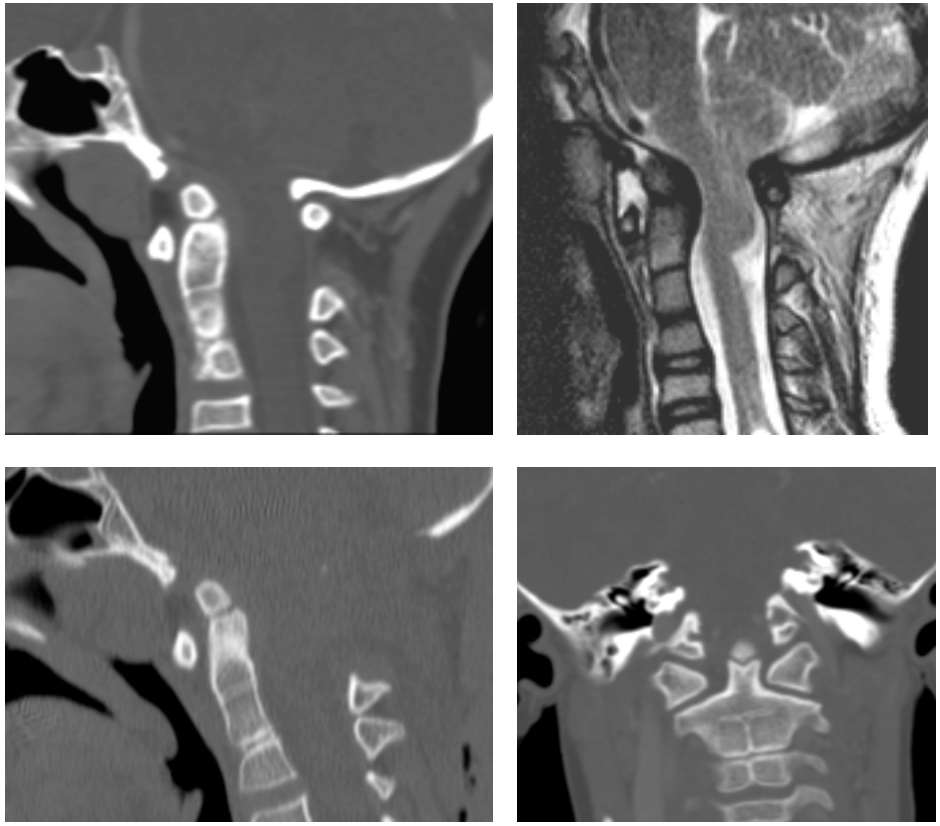

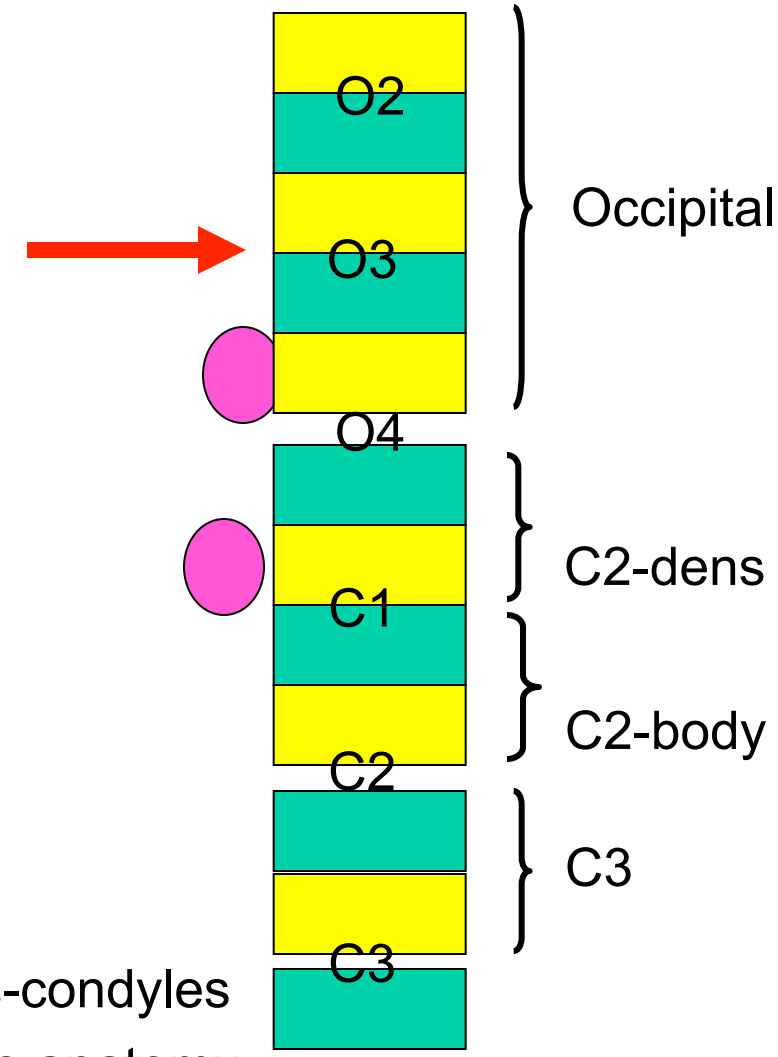

Prominent dens & short clivus

Associated hypoplasia of jugular tubercles-condyles

Neo-articulation with unknown ligamentous anatomy

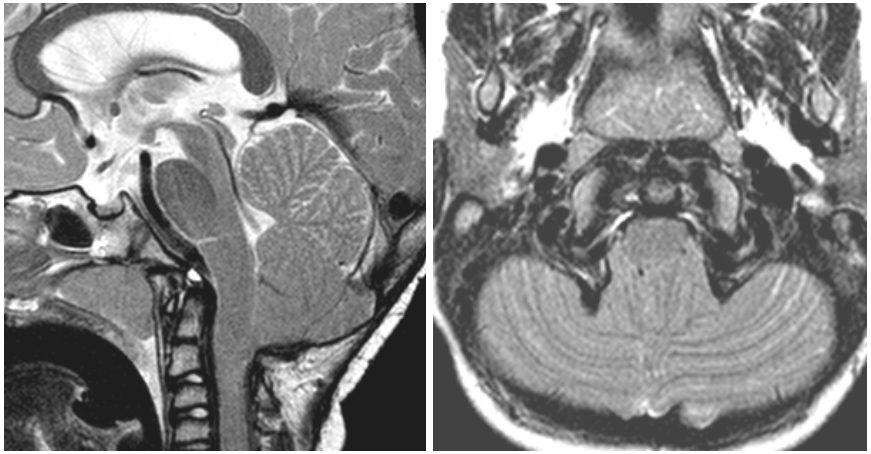

Short clivus, basal invagination

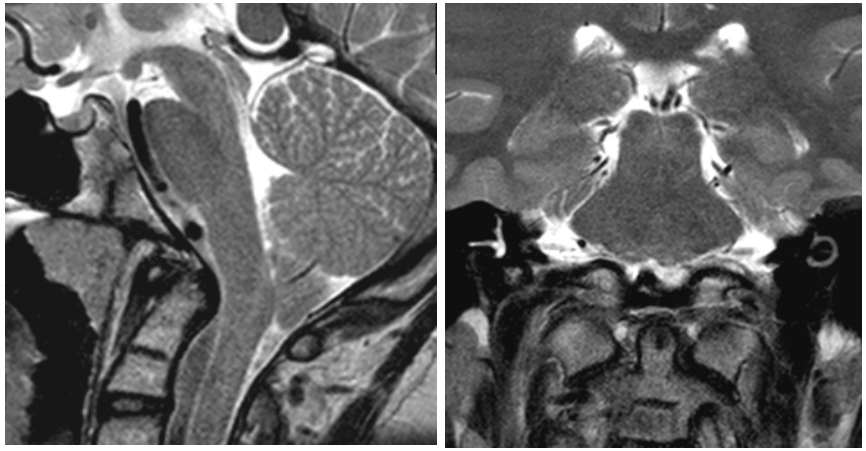

Short clivus, small condyles

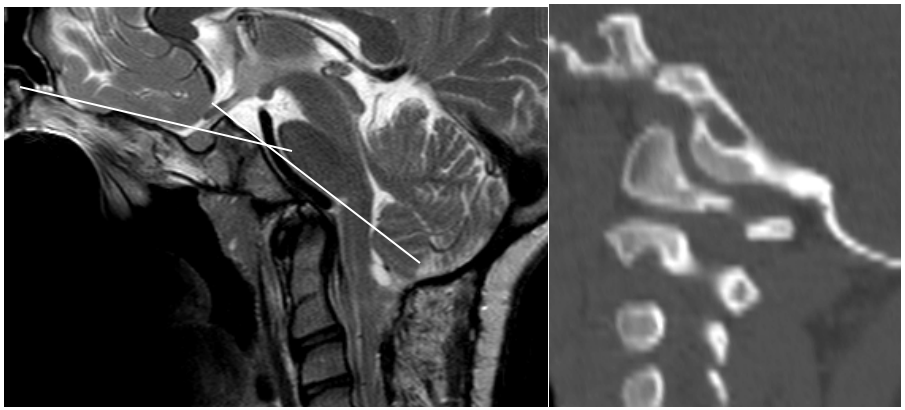

Short clivus, platybasia (>140º), hypoplastic condyle, long dens

Short clivus, basal invagination, long dens

Condylus tertius

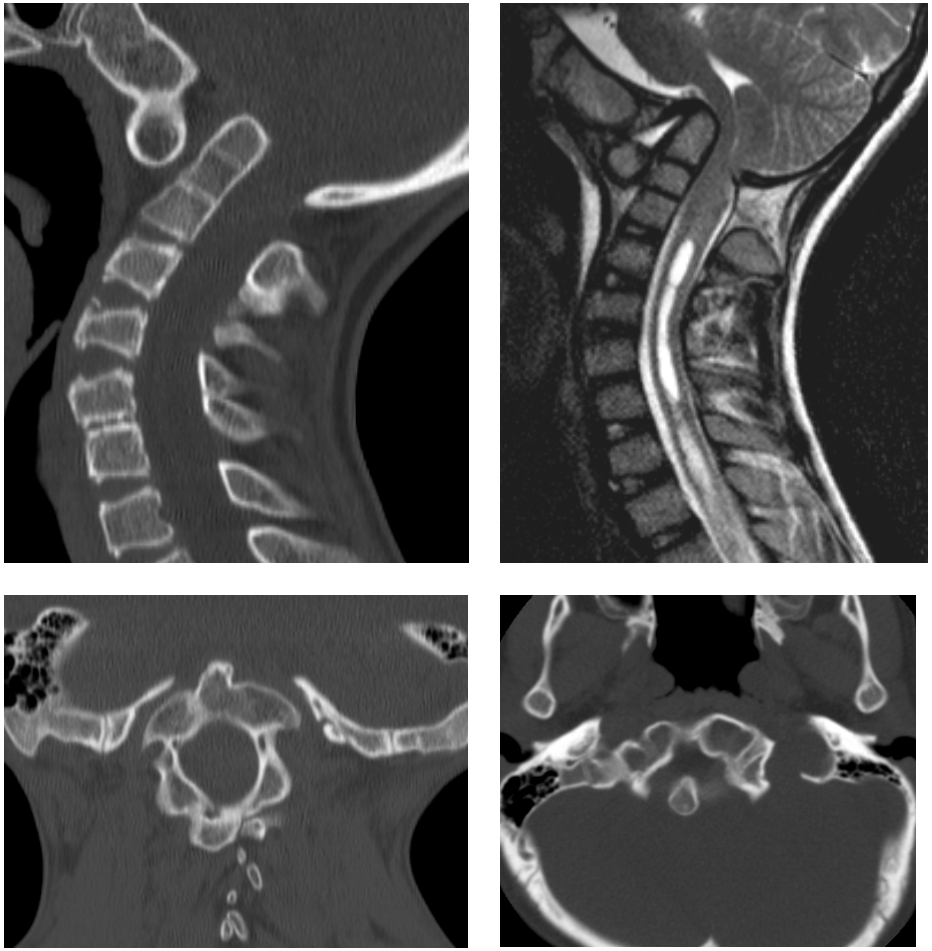

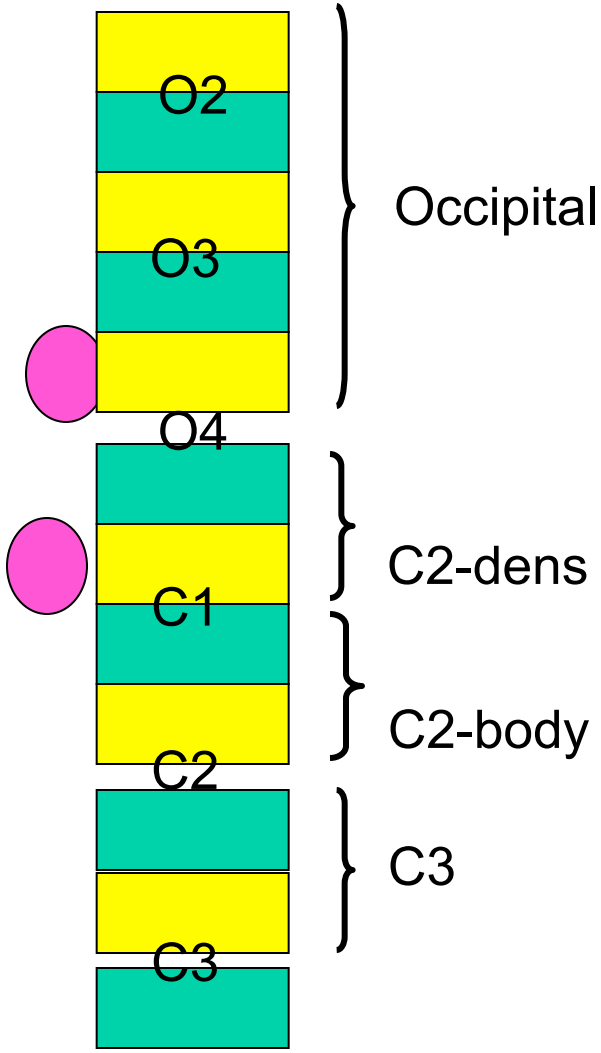

Fused hypocentra with undivided O4, long dens and invagination, abnormal ligaments

Summary

- In assessing Chiari 1 deformity, need to dissociate
  1. cause and mechanism
  2. location of tonsils with impact on CSF flow and cord
  3. CVJ dynamics and osteo-neural relationships (no Chiari possible)

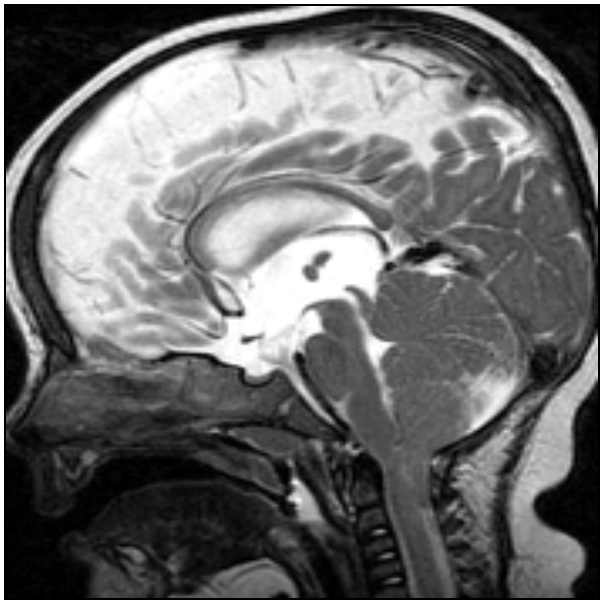

Conclusions

- Chiari I deformity results from mechanical processes (container/content), similar to classical tonsillar herniation
- Accordingly, tonsillar dislocation is a feature of many different disorders
- Tonsillar dislocation has its own pathology (CSF dynamics, local compression)
- CVJ malformations result in abnormal osteo-neural relationships (retroverted dens) and a specific pathology
- Abnormal CVJ segmentation likely associated with specific but unknown anatomy of corresponding ligaments