ÉCOLE POLYTECHNIQUE
FÉDÉRALE DE LAUSANNE

4D MRI quantification of CSF velocities with comparison to computational fluid dynamics (CFD) simulations

April 26, 2012

American Society of Neuroradiology, 50th Annual Meeting
CSF and hydrocephalus study group

Bryn A. Martin[1]

Theresia I. Yiallourou[1], Jan-Robert Kroeger[2], Nikolaos Stergiopulos[1], A.C. Bunck[2]

[1]Laboratory of Hemodynamics and Cardiovascular Technology, EPFL, Switzerland
[2]Department of Clinical Radiology, University Hospital of Muenster, Germany
[3]Department of Radiology, University of Basel, Switzerland

Ongoing research in CSF hydrodynamics

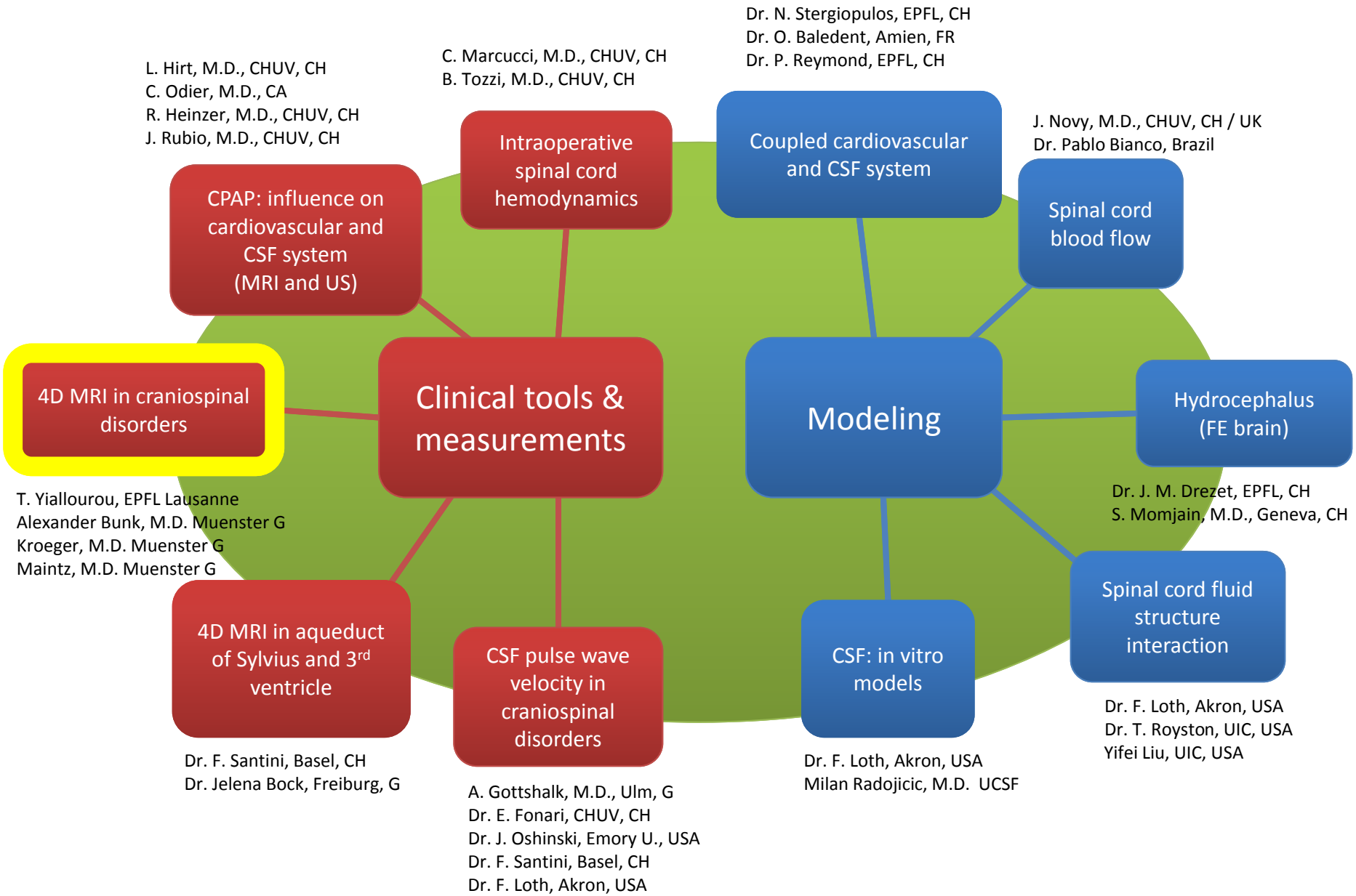

Motivation

- Abnormal CSF hydrodynamics have been implicated in many craniospinal disorders

Hydrocephalus

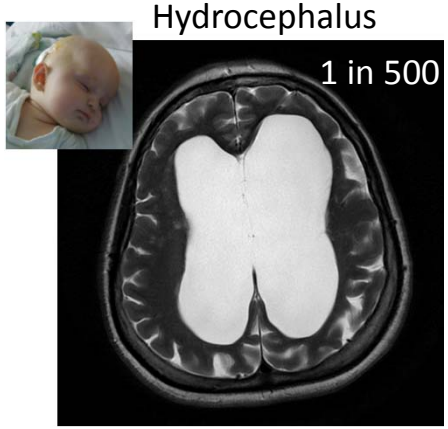

Syringomyelia

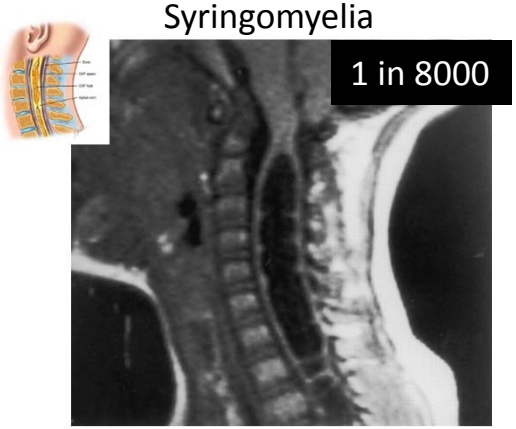

Chiari malformation

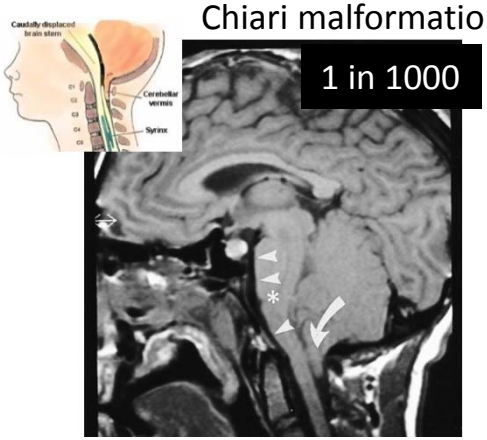

Tethered cord / Spina Bifida

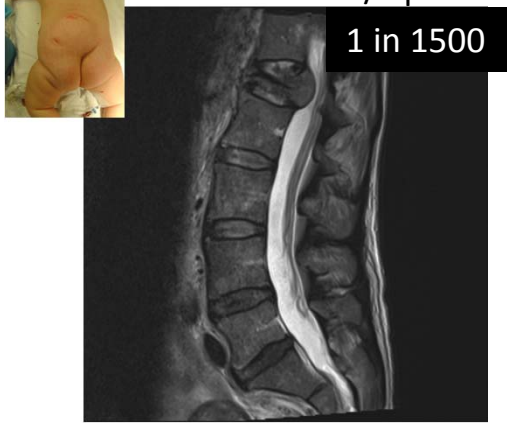

ninds.nih.gov/disorders/

Need for CSF biomechanics research

- The underlying biomechanical forces that contribute to craniospinal disorders are not well understood.
- Engineers + medical doctors are helping to do in CSF hydrodynamics what has been done in hemodynamics.

Background: CSF flow in cervical spine

- Anterior / posterior flow differences
- Nerve roots appear to impact flow

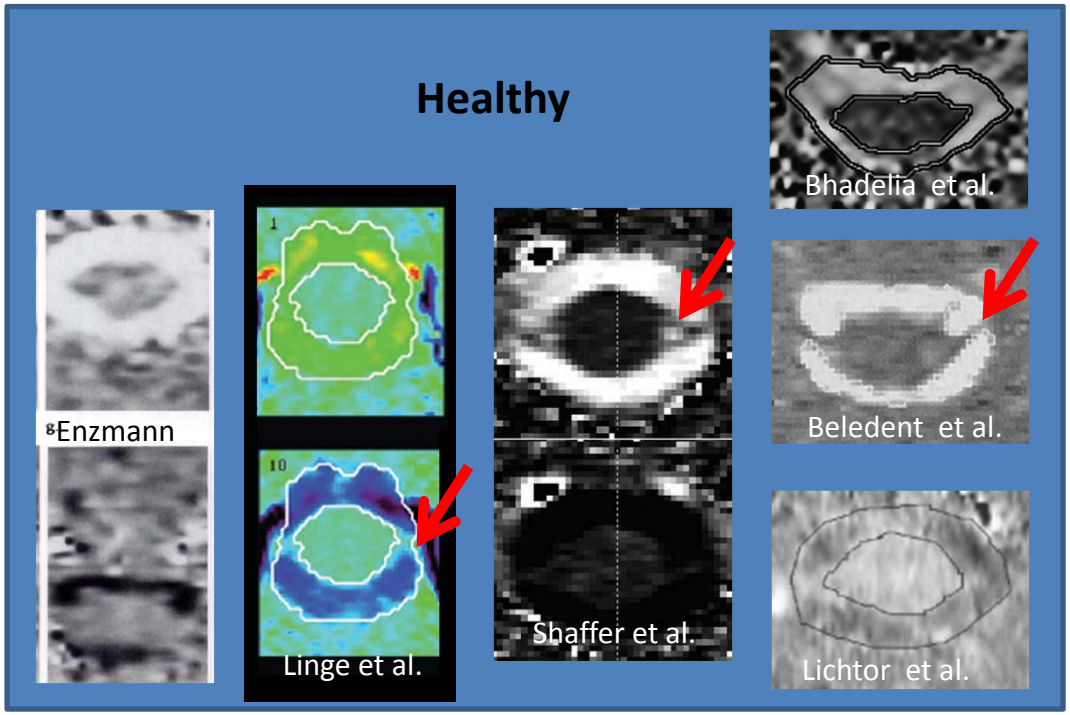



Linge SO et al.. CSF flow dynamics at the craniovertebra. AJNR American journal of neuroradiology. 2010;31(1):185-92.
Krueger KD, et al.. Peak CSF velocities. AJNR American journal of neuroradiology. 2010;31(10):1837-41.
Shaffer, et al.. *Neurological research* **33**, 247-260, doi:10.1179/016164111X12962202723805 (2011).
Martin, B. A., et al. Syringomyelia hydrodynamics. *J Biomech Eng* **127**, 1110-1120 (2005).
Lichtor, et al., Noncommunicating. *Spine* **30**, 1335-1340, doi:00007632-200506010-00019 [pii] (2005).
Quigley, M. F., et al. Cerebrospinal fluid flow. *Radiology* **232**, 229-236 (2004).
Brugieres, P. *et al.* CSF flow measurement in syringomyelia. *AJNR Am J Neuroradiol* **21**, 1785-1792 (2000).
Bhadelia, R. A., et al. Cerebrospinal fluid pulsation. *Neuroradiology* **39**, 258-264 (1997).
Enzmann, D. R. & Pelc, N. J. Normal flow... *Radiology* **178**, 467-474 (1991).

4D MRI in cervical spine

- Recently employed technique to visualize CSF flow
- Not yet quantitatively analyzed against CFD

Healthy

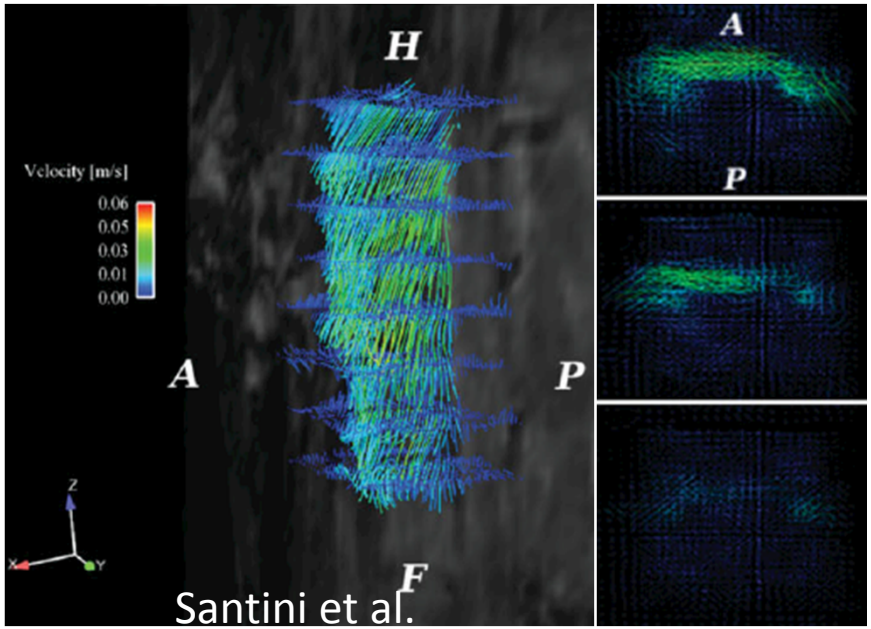

Chiari patient

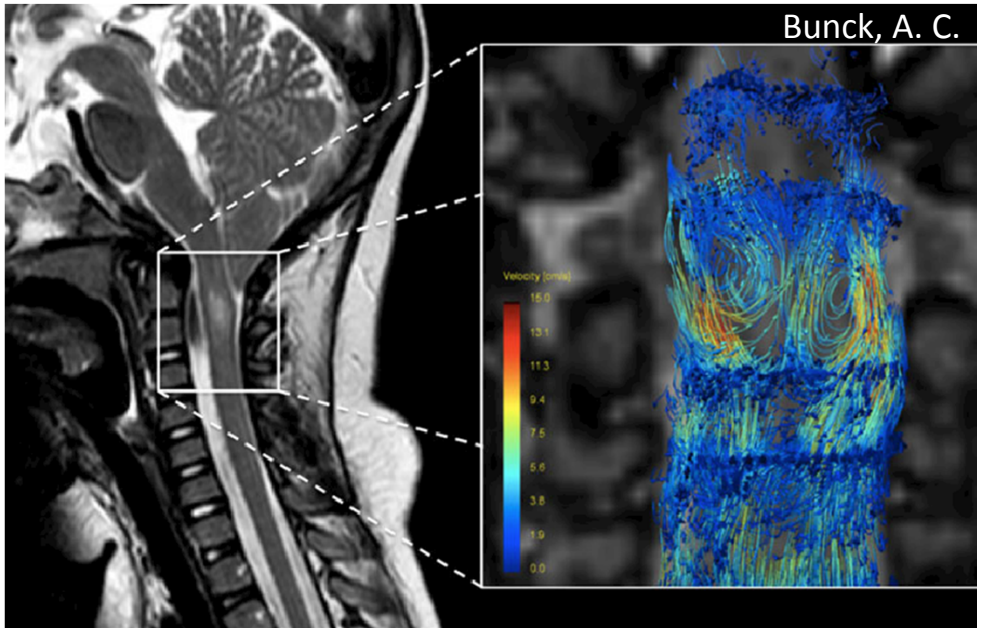

Bunck, A. C. *et al.* Magnetic resonance 4D flow characteristics of cerebrospinal fluid at the craniocervical junction and the cervical spinal canal. *European radiology* **21**, 1788-1796, doi:10.1007/s00330-011-2105-7 (2011).
Santini, F., et al. Time-resolved three-dimensional... *Magnetic resonance in medicine :* **62**, 966-974, doi:10.1002/mrm.22087 (2009).

Background: CFD in spine

- What level of CFD simulation complexity is needed?

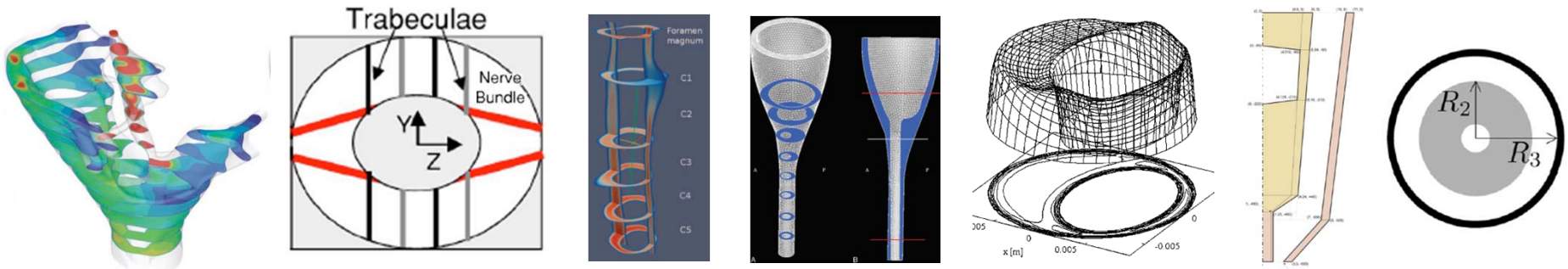

a. b. c. d. e. f. g.

Author	Year	Geometry	Tissue motion	Arachnoid trebeculae	Nerve roots / ligaments
a. Gupta et al.	2009	3D subject specific	No	Yes	No
b. Stockman	2007	2D idealized	No	Yes	Yes
c. Linge et al. Roldan et al. Present study	2010?	3D subject specific	No	No	No
d. Linge et al.	2009	3D idealized	No	No	No
e. Loth et al.	2001	2D concentric ellipse	No	No	No
f. Bertram	2005-12	2D idealized axi-symmetric	Yes	No	No
g. Cirovic Elliott/Carpenter Lockey?	2005-12	2D concentric tube with constant diameter	Yes	No	No

Objective

1. Assess 4D MRI measurements of cervical CSF flow in healthy and patients with CSF blockage at the foramen magnum.
2. Compare 4D MRI measurements to subject specific 3D CFD.

Our study:

- 3 healthy subjects
- 4 patients with craniospinal instabilities at the foramen magnum

Work in progress: A. Bunck, J. R. Kröger, Bryn A. Martin, et al. "Magnetic resonance velocity mapping of 4D cerebrospinal fluid flow in Chiari I malformation with and without syringomyelia," European Journal of Radiology

Methods

- 4D MRI CSF flow measurements by A. C. Bunck et al.[1]
- Processing & visualization of 4D MRI with GT Flow software
- Reconstruction of the 3D geometry (ITK snap)
- CFD simulation (rigid wall / newtonian fluid (water) / Unsteady flow / ANSYS CFX)

A. C. Bunck et al. "Magnetic resonance 4D flow characteristics of cerebrospinal fluid at the craniocervical junction and the cervical spinal canal," *European Radiology,* vol. 21, pp. 1788-96, Aug 2011.

4D MRI in cervical spine

Healthy

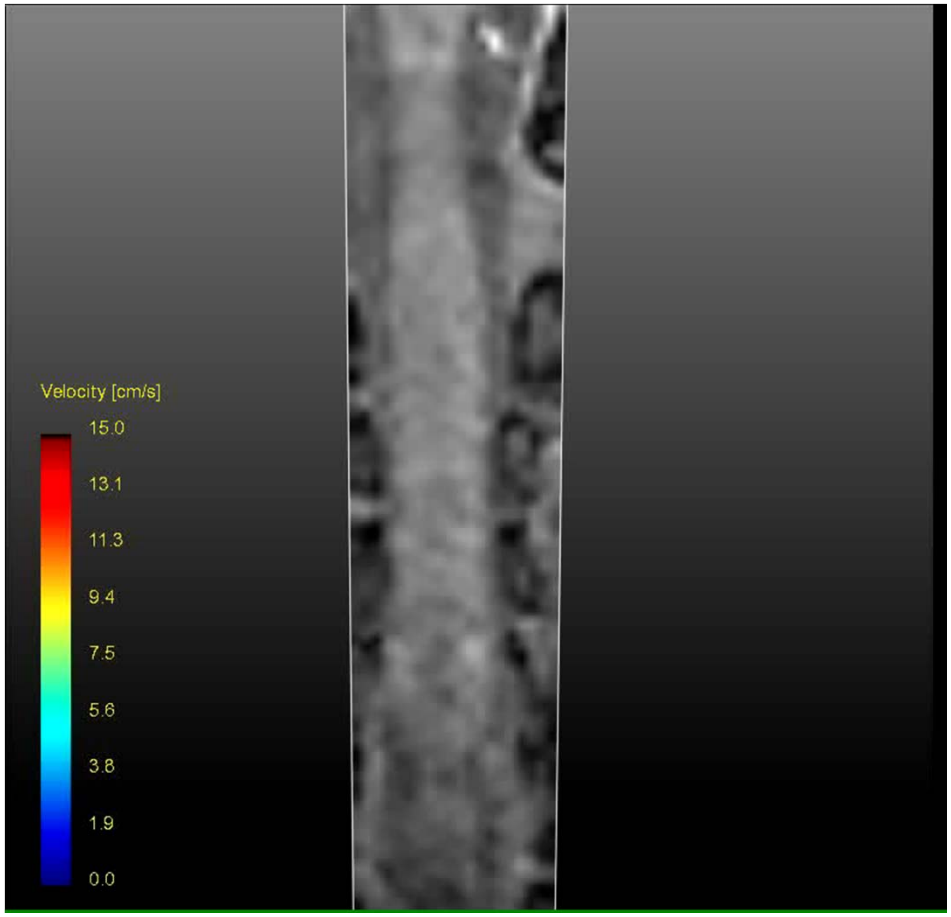

Chiari patient

Bunck, A. C. *et al.* Magnetic resonance 4D flow characteristics of cerebrospinal fluid at the craniocervical junction and the cervical spinal canal. *European radiology* **21**, 1788-1796, doi:10.1007/s00330-011-2105-7 (2011).

Comparison of 4D MRI and 3D CFD

Compare in terms of:

1. Velocity profiles
2. Peak flow velocities

Method for velocity profile comparison

4D MRI

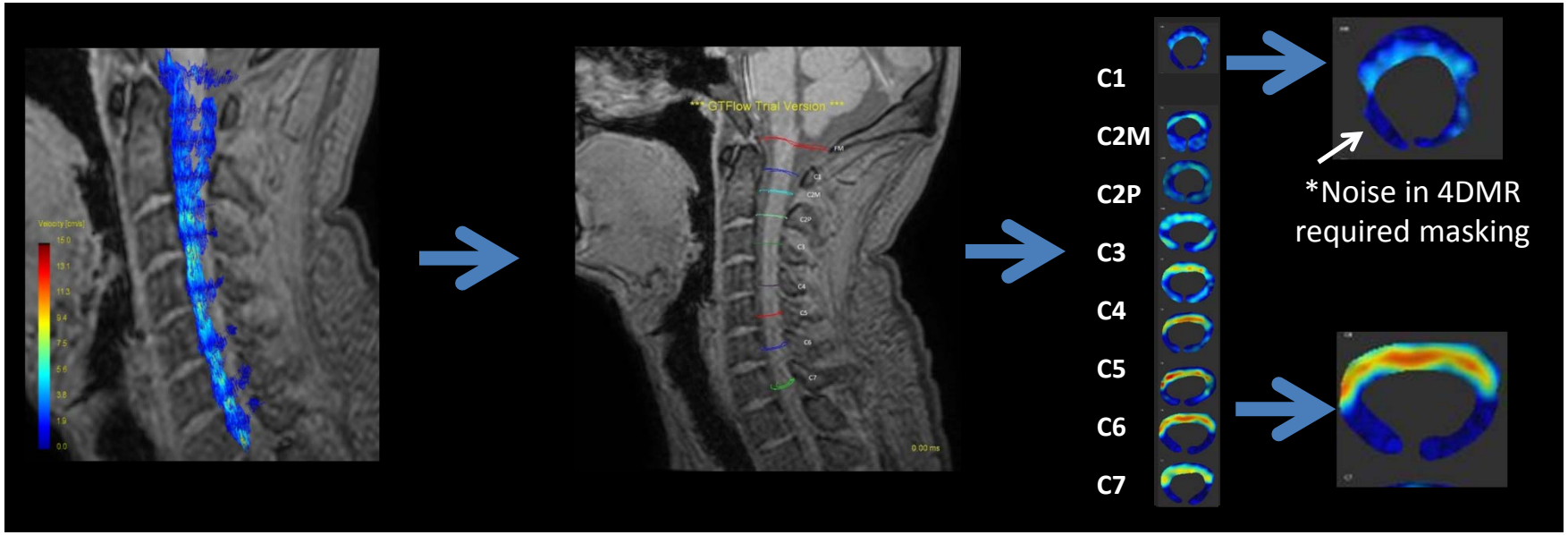

3D CFD

High res. MRI scan

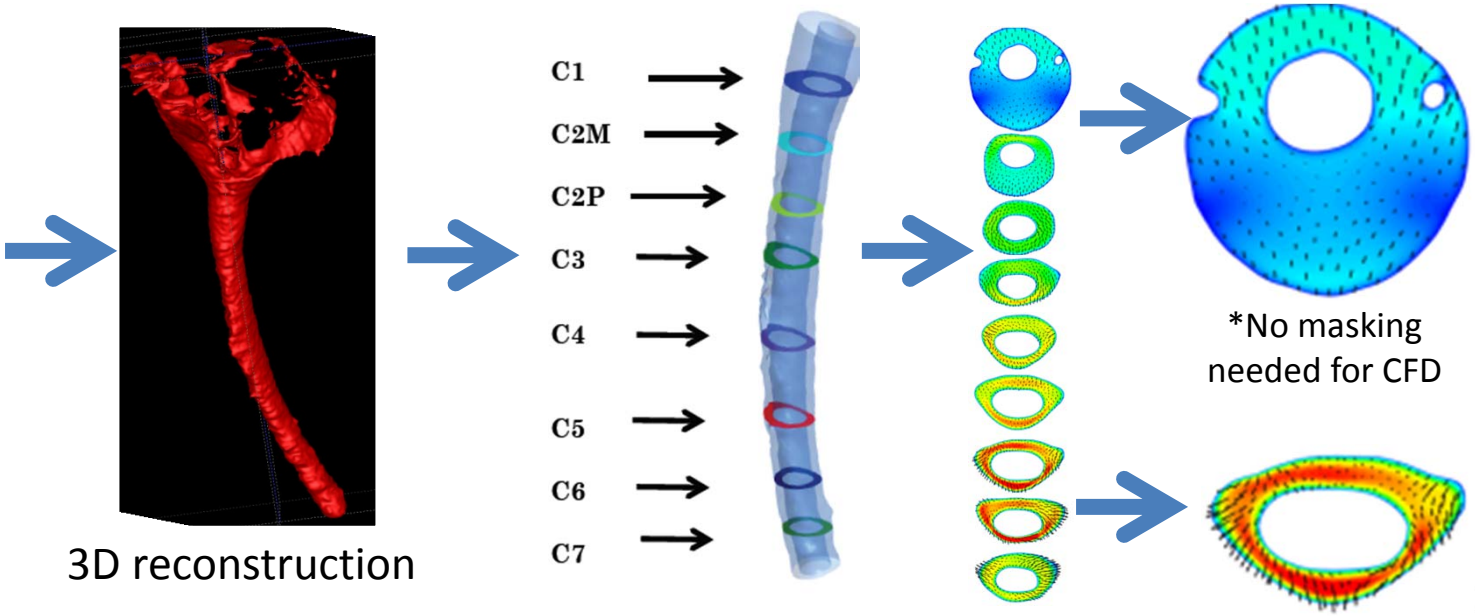

3D reconstruction

Flow boundary condition

- Due to noise in 4D MRI, we used the 4D MRI location with the greatest peak flow rate (best signal) for flow BC.
- Flow was input at the caudal end of the model (P=0 at outlet)
- Blunt velocity profile w/ geometry extended at flow inlet.

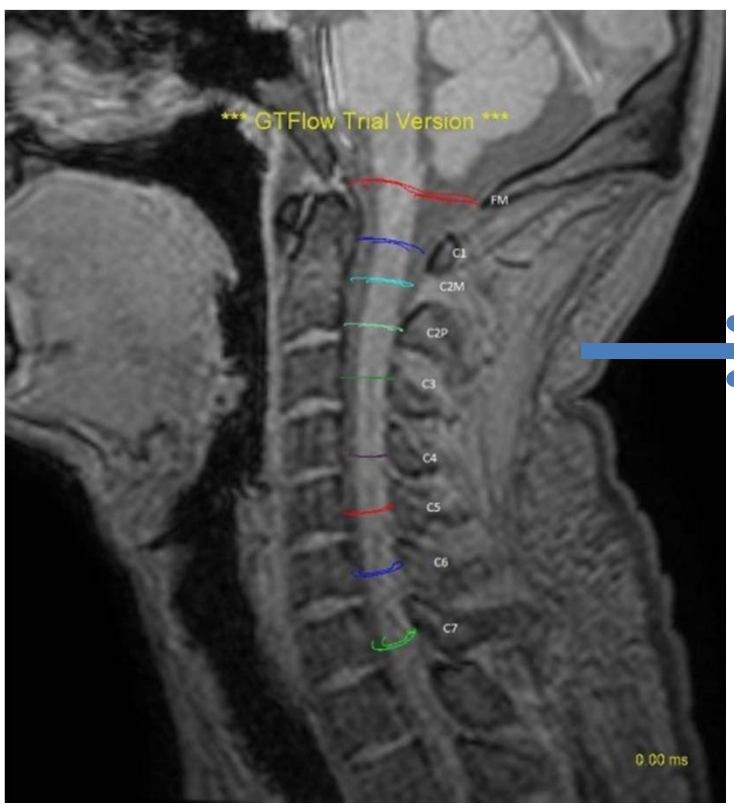

4D MRI

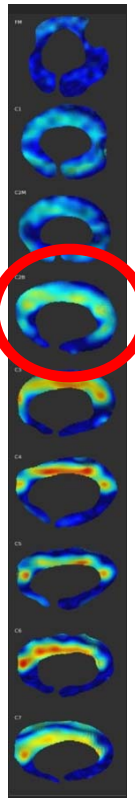

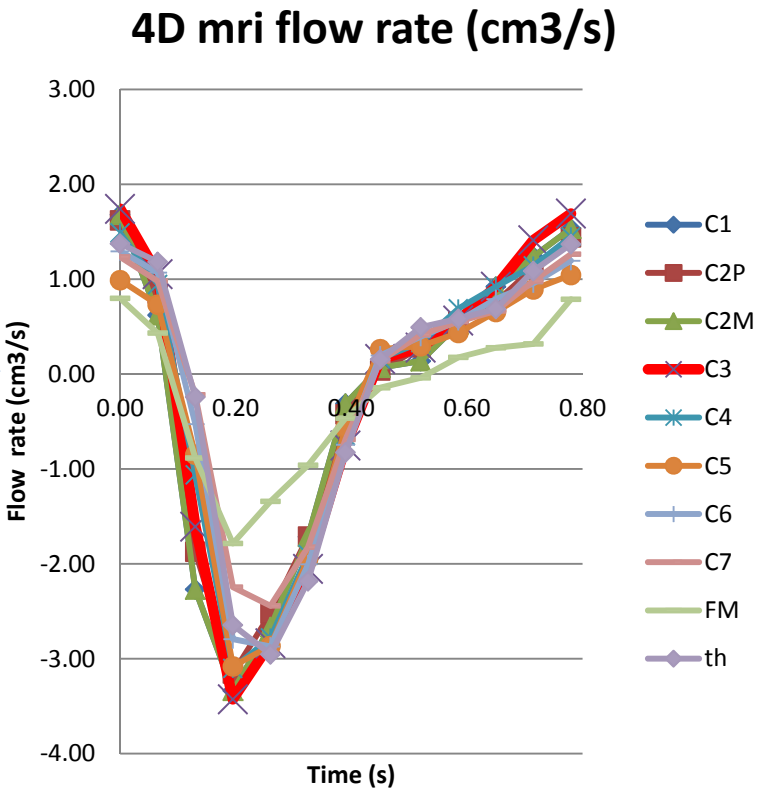

Results: velocity profile comparison

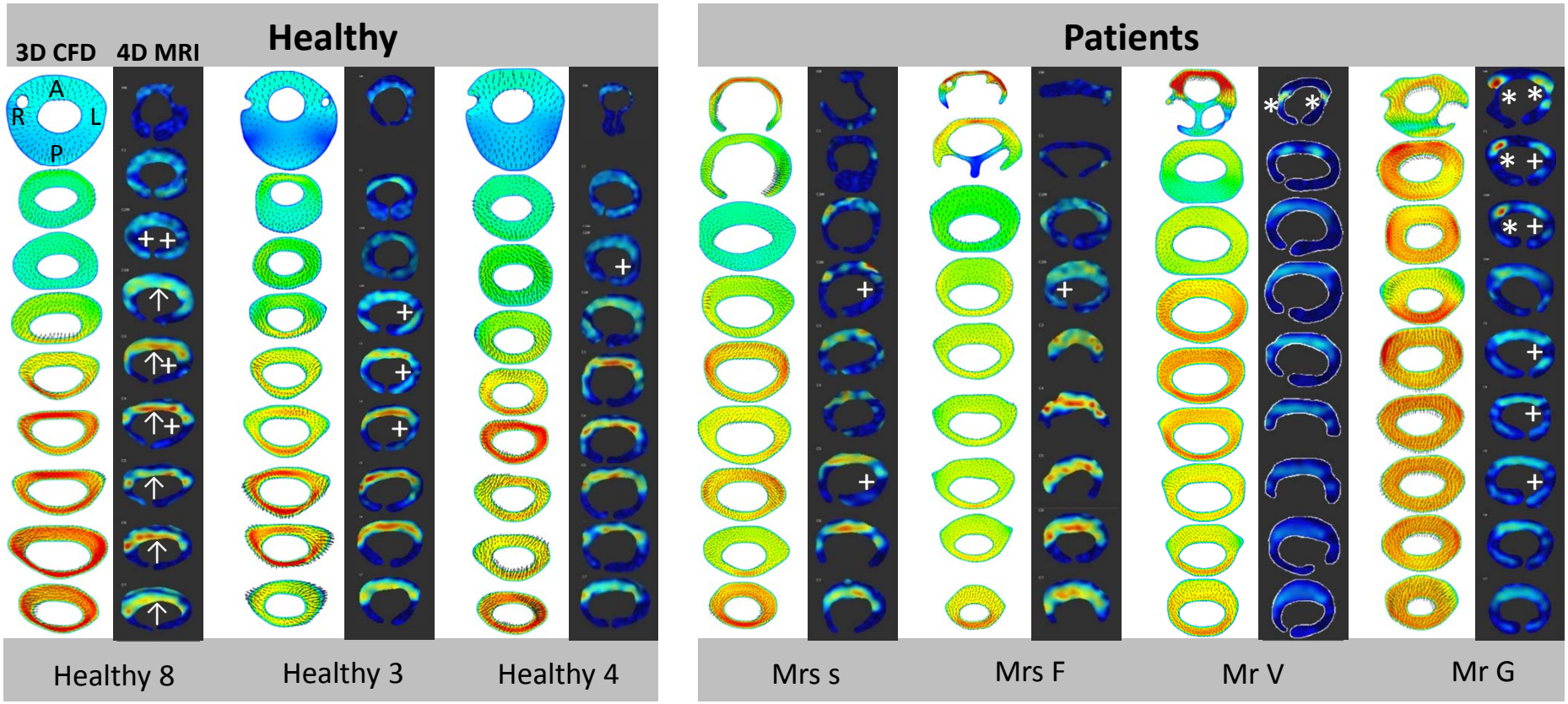

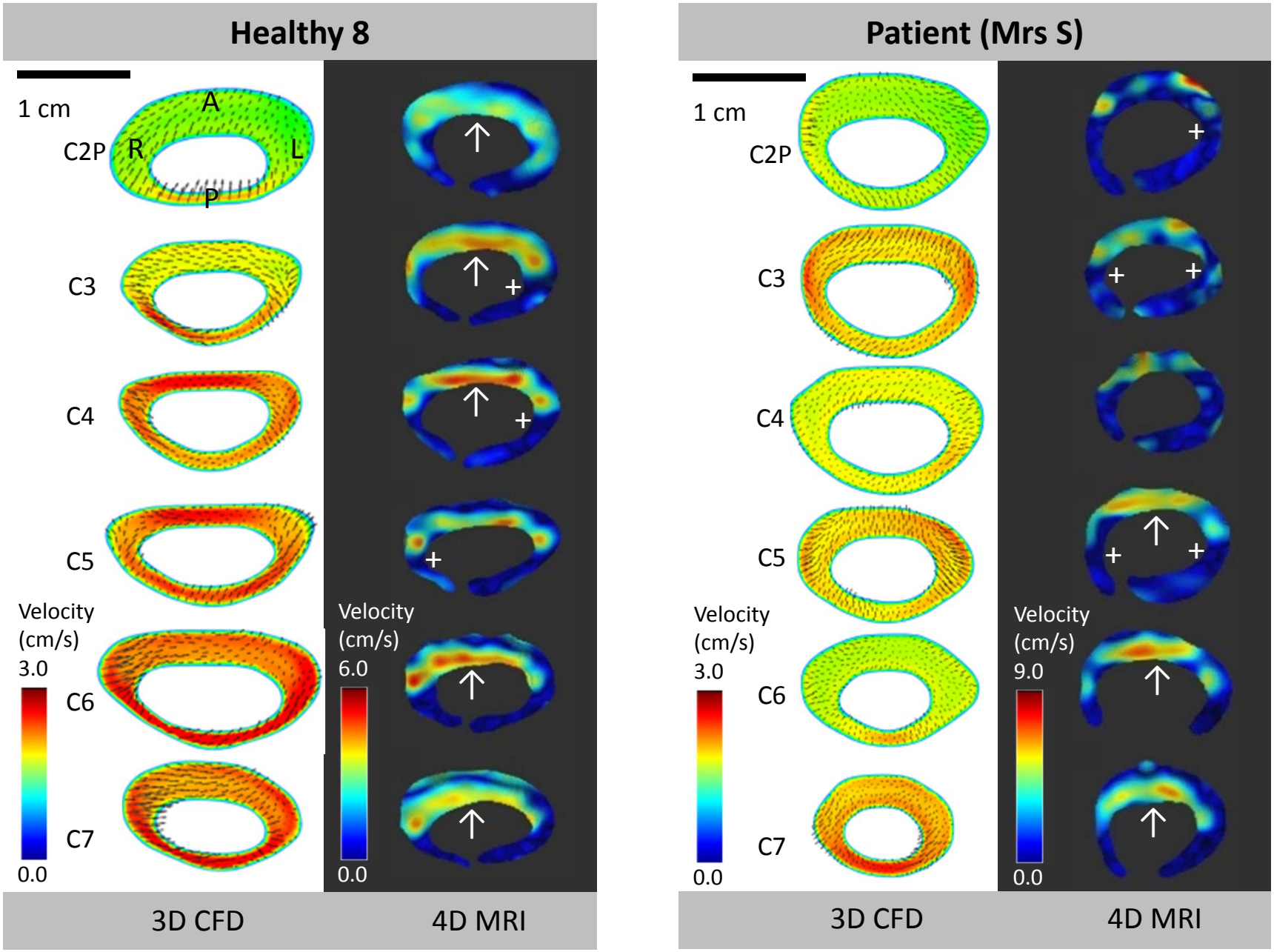
Healthy 8
1 cm
A
C2P
R
L
P
C3
C4
C5
C6
C7
Velocity
(cm/s)
3.0
0.0
Velocity
(cm/s)
6.0
0.0
3D CFD
4D MRI
Patient (Mrs S)
1 cm
C2P
C3
C4
C5
C6
C7
Velocity
(cm/s)
3.0
0.0
Velocity
(cm/s)
9.0
0.0
3D CFD
4D MRI

Results: comparison of peak velocities

- 4D MRI was consistently higher than 3D CFD
- Differences were pronounced in patients near brain base (FM)

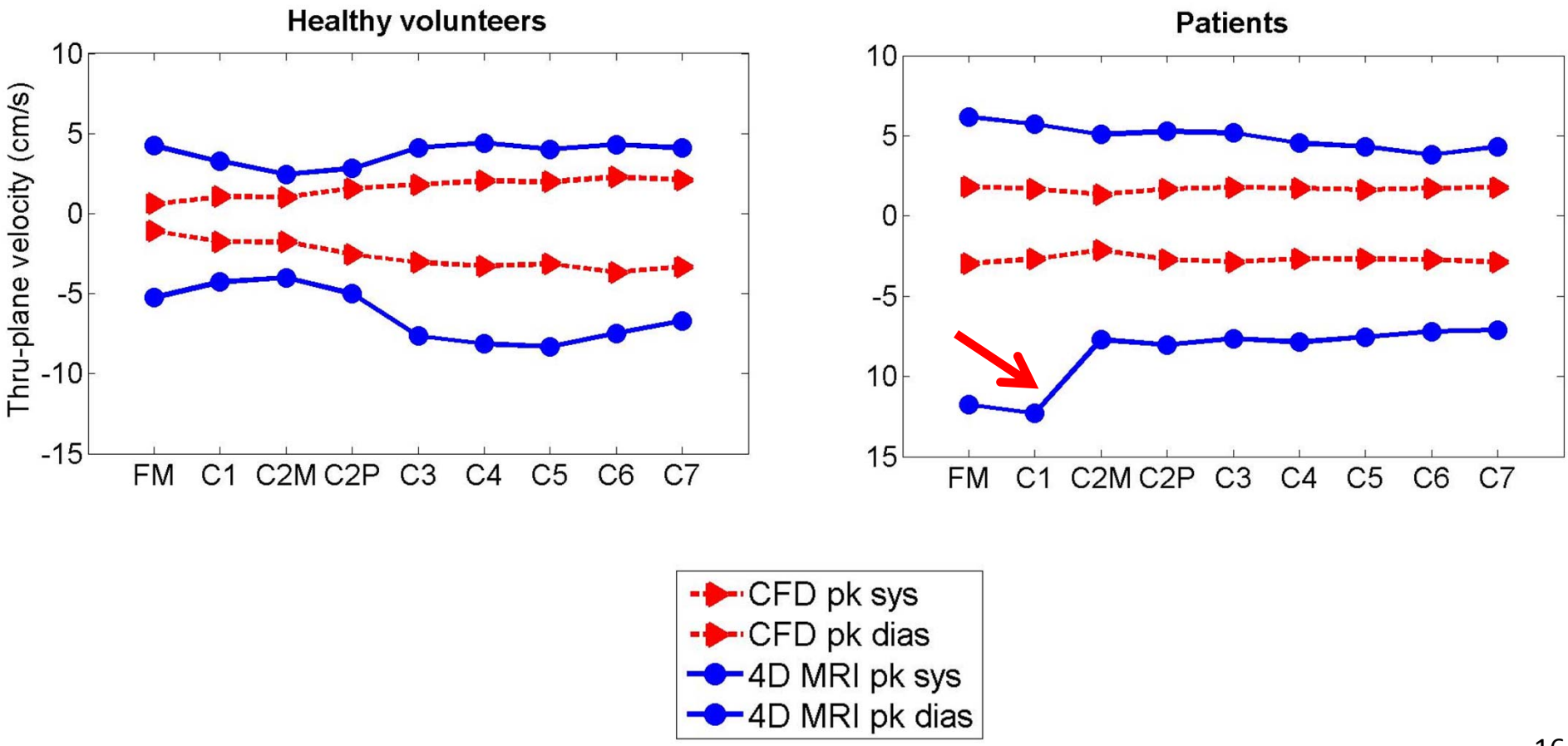

Interesting observation: For Mrs S. and Mrs F, CSF flow was present in the mid/lower cervical spine but not at the foramen magnum!

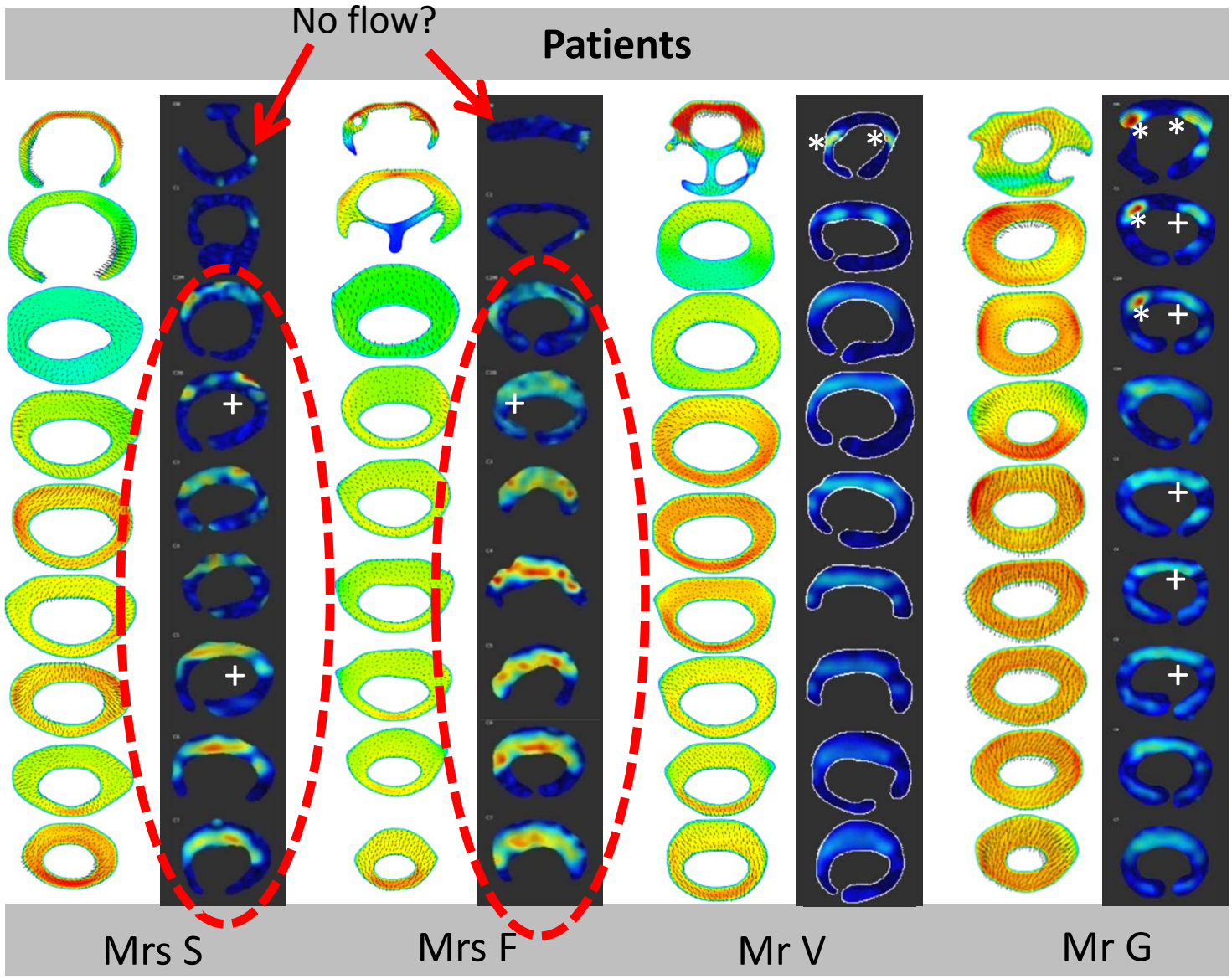

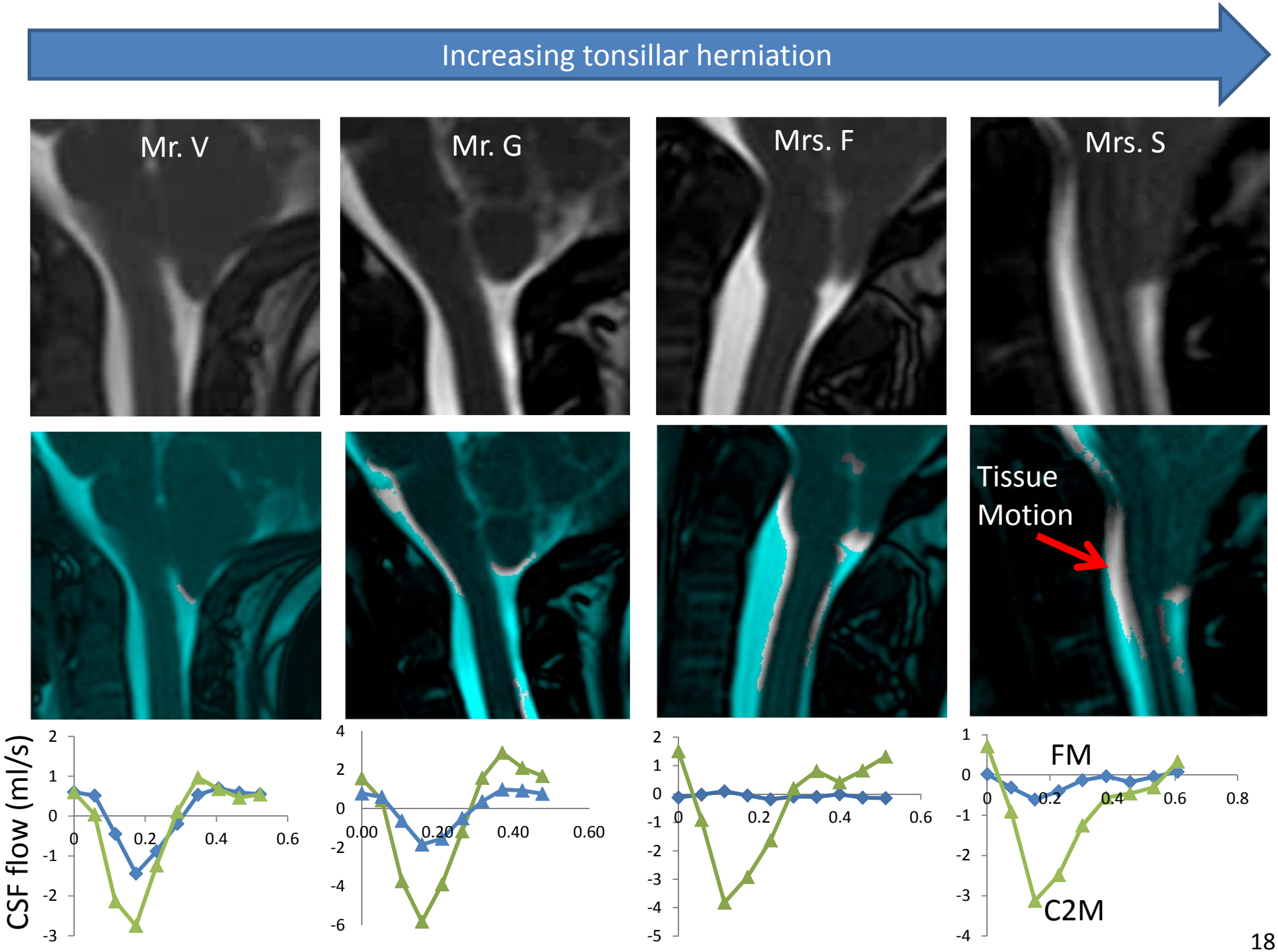
Increasing tonsillar herniation
Mr. V
Mr. G
Mrs. F
Mrs. S
Tissue Motion
CSF flow (ml/s)
FM
C2M

Tonsillar herniation and CSF flow jets

Mild herniation at FM

- Flow stenosis
- Elevated pressure gradients at FM & stress on tissue
- Flow Jets
- Mild reduction in CSF pulse amplitude at FM
- Mild tissue displacement
- Tissue remodeling?

Severe herniation at FM

- Flow blockage
- No flow jets
- CSF pulse zero at FM
- Severe tissue displacement
- Lower cervical CSF pulse from bulk tissue displacement?

Why are there differences in the flow field obtained by subject specific 3D CFD compared to 4D MRI?

Tissue motion

- Alters flow field
- Quantified in literature (Cousins et al., Greitz)

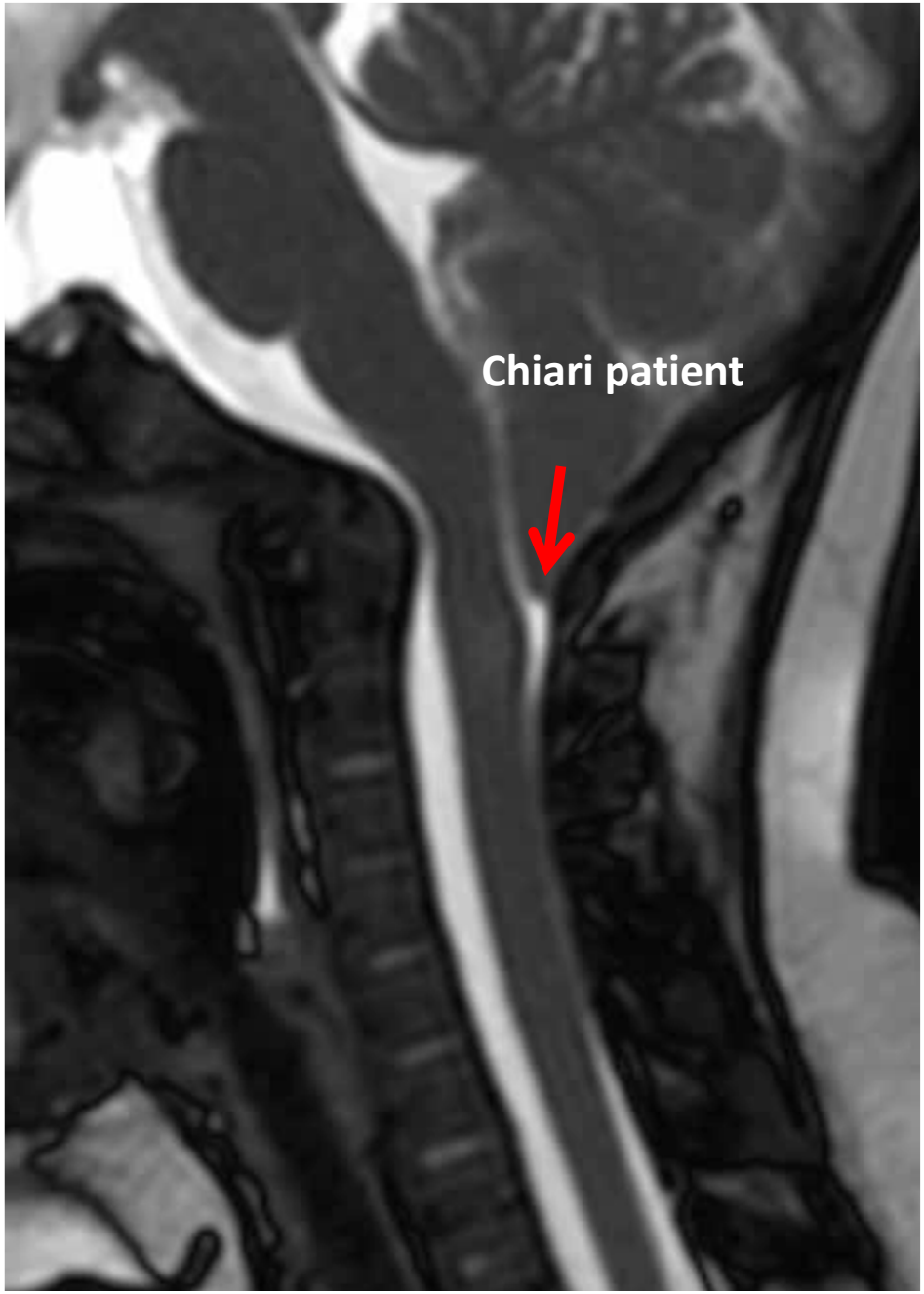

Cousins, J. & Haughton, V. Motion of the cerebellar tonsils in the foramen magnum during the cardiac cycle. *AJNR. American journal of neuroradiology* **30**, 1587-1588, doi:10.3174/ajnr.A1507 (2009).
1991-Greitz-Neuroradiology-CSF Piston

*Unpublished imaging video.

Error/noise from MRI

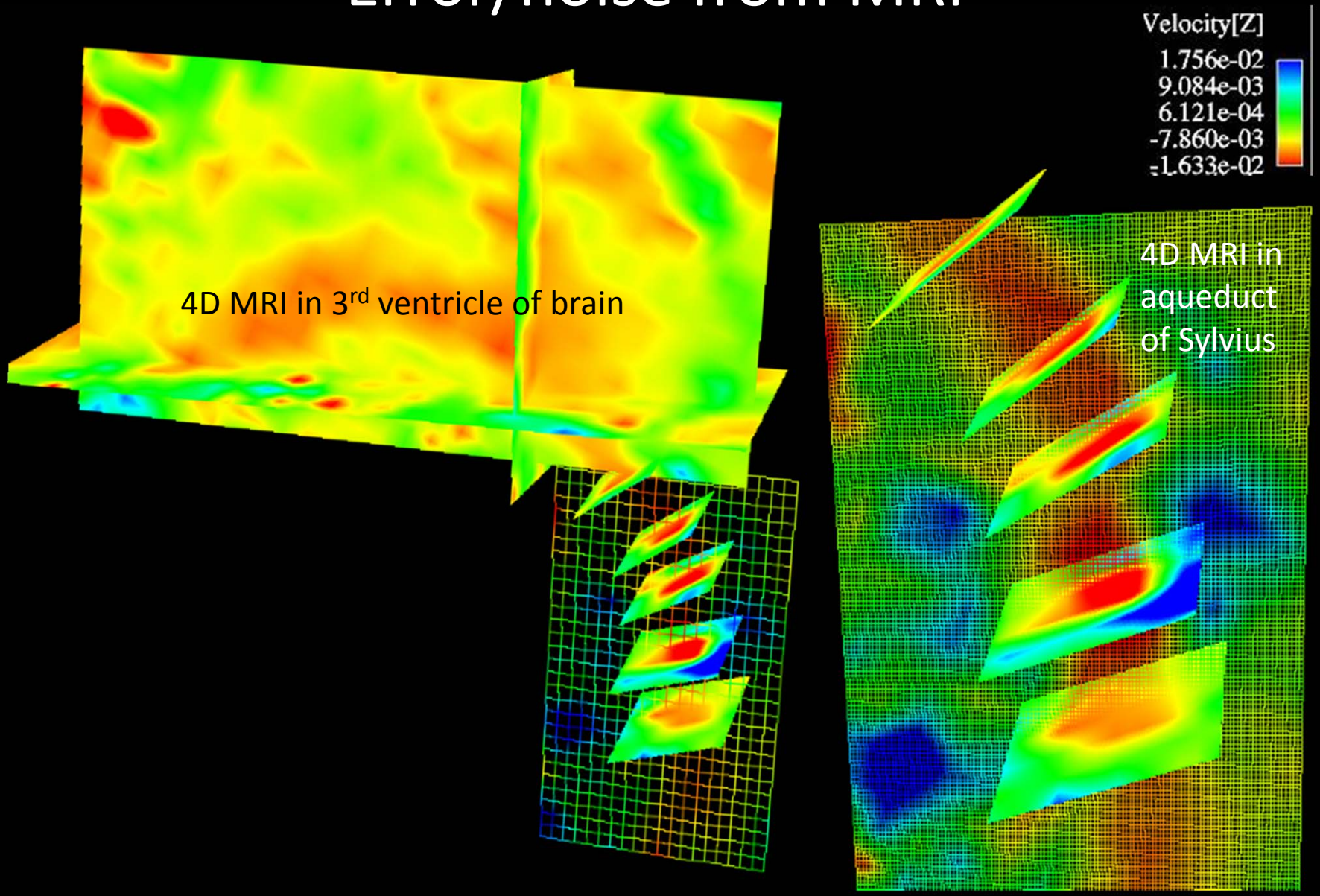

Inconsistent / inaccurate CSF mesh

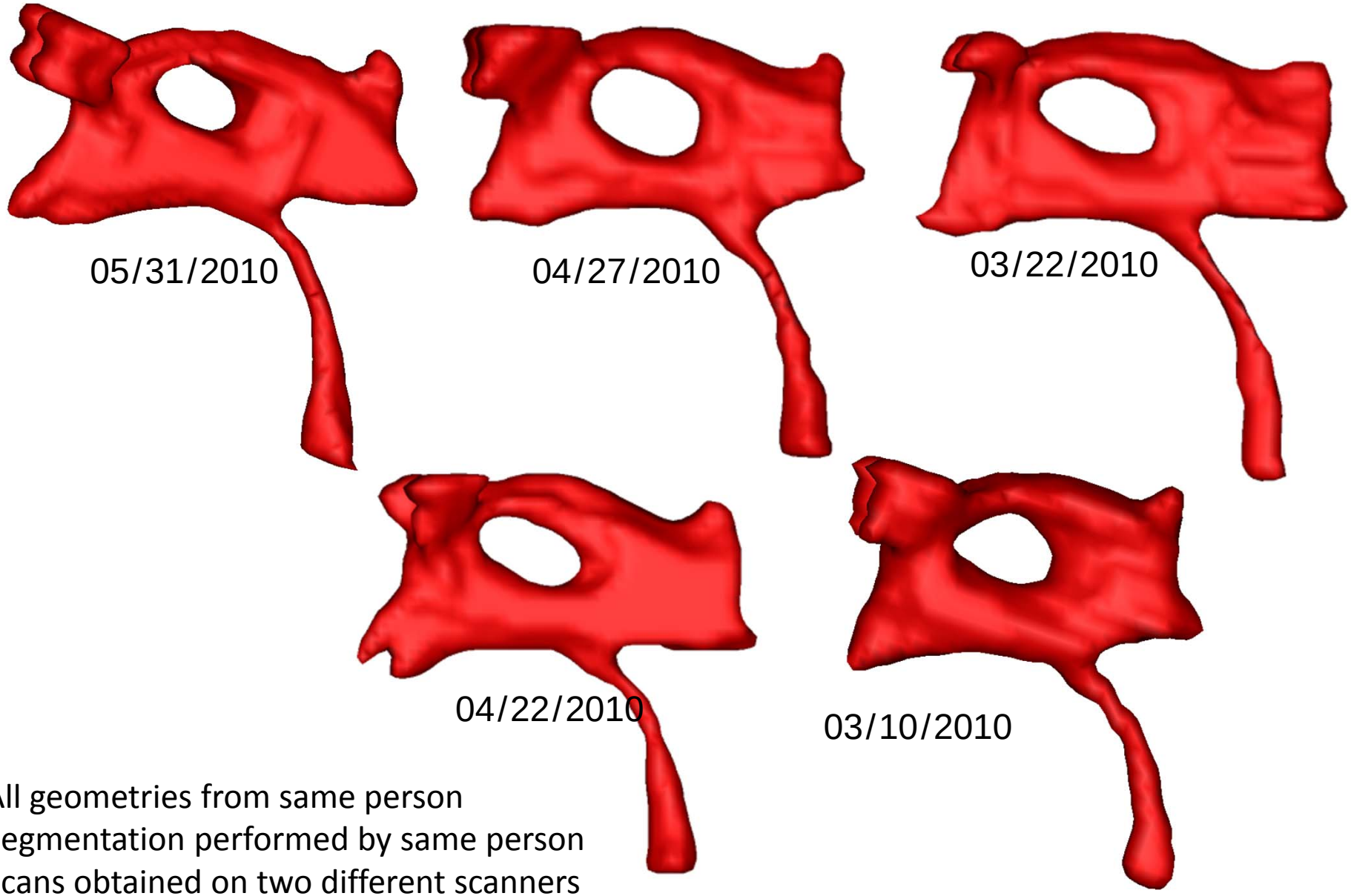

All geometries from same person
Segmentation performed by same person
Scans obtained on two different scanners

Error from neglect of fine structure

- Arachnoid trebeculae within the spinal subarachnoid space were neglected. Is the distribution isotropic?

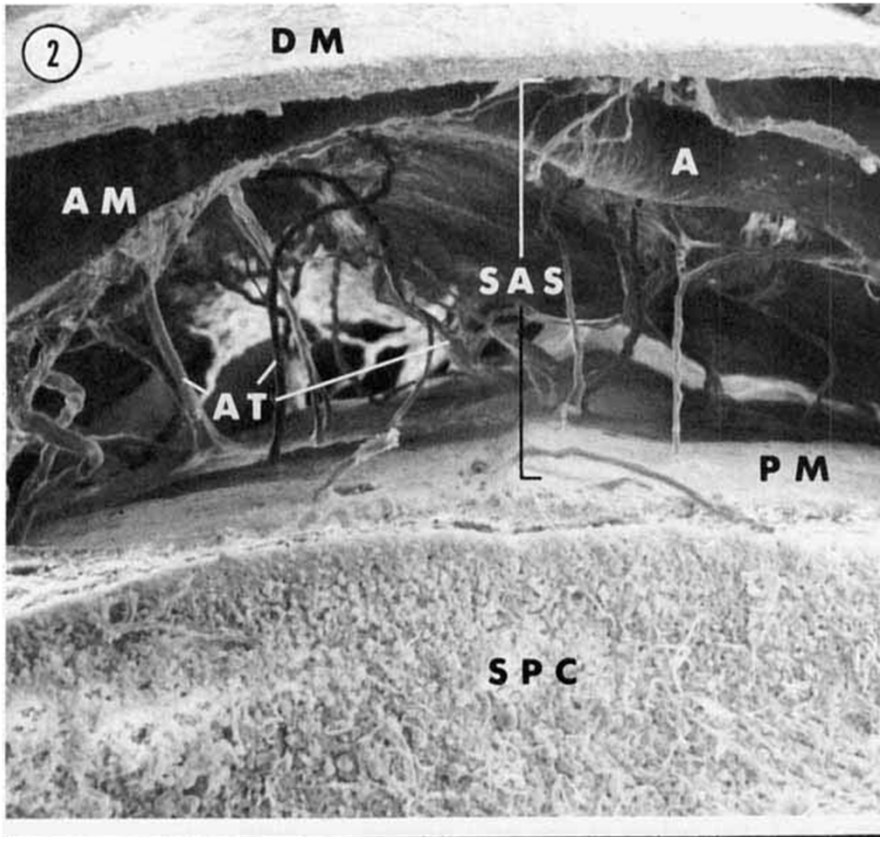

(2) Cloyd, M. W. and F. N. Low (1974). "Scanning electron microscopy of the subarachnoid space in the dog. I. Spinal cord levels." The Journal of comparative neurology **153**(4): 325-368.

Error in CFD from neglect of other structures

- Nerve roots
- Denticulate ligaments

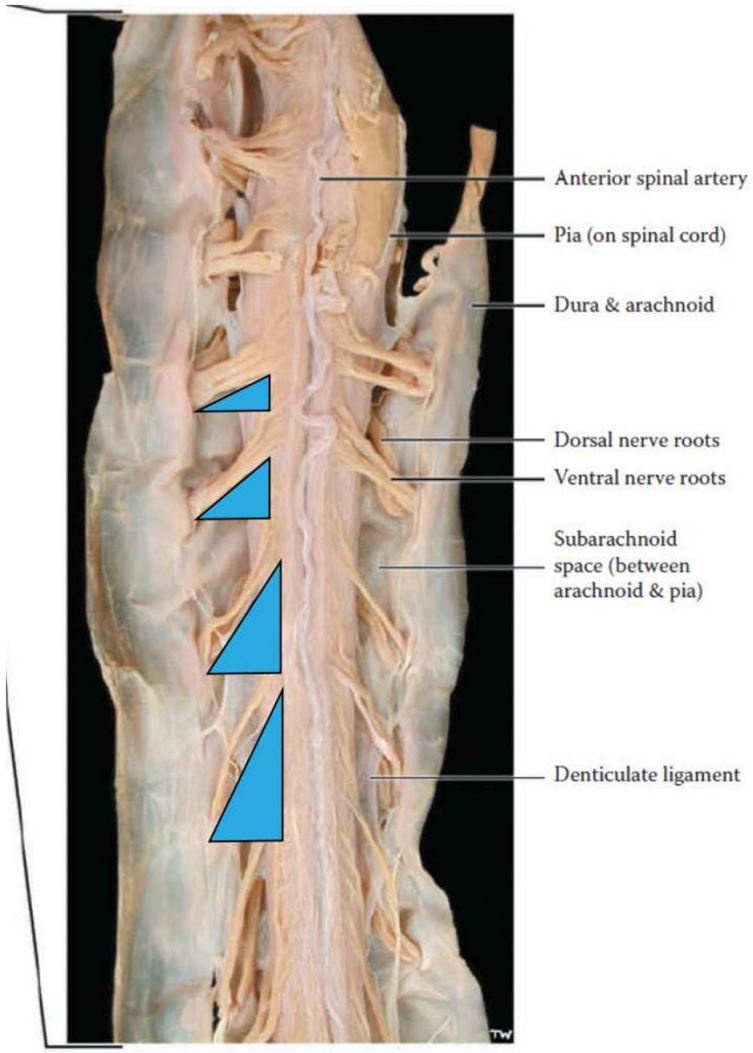

Future directions

- CFD in cervical spine with and w/o fine anatomy

Our new model in development

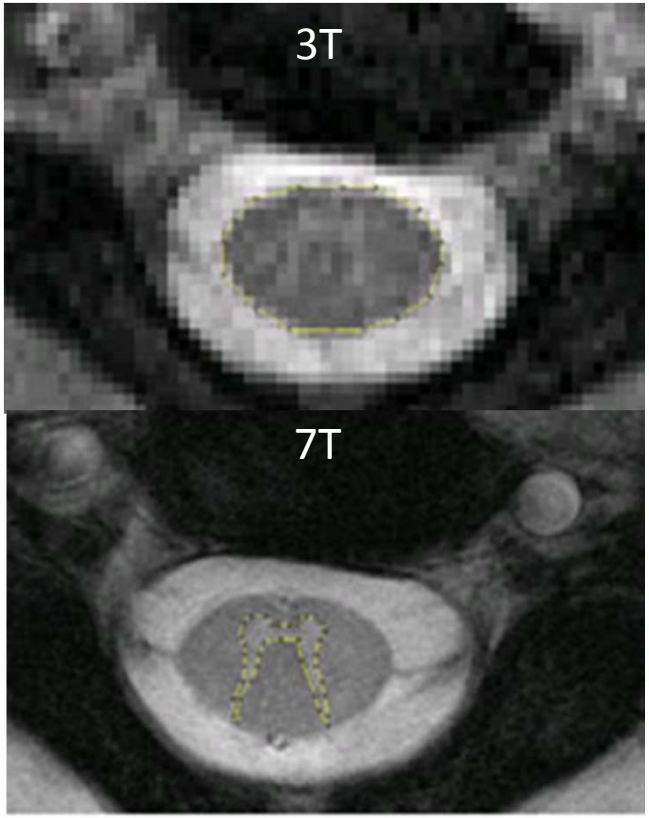

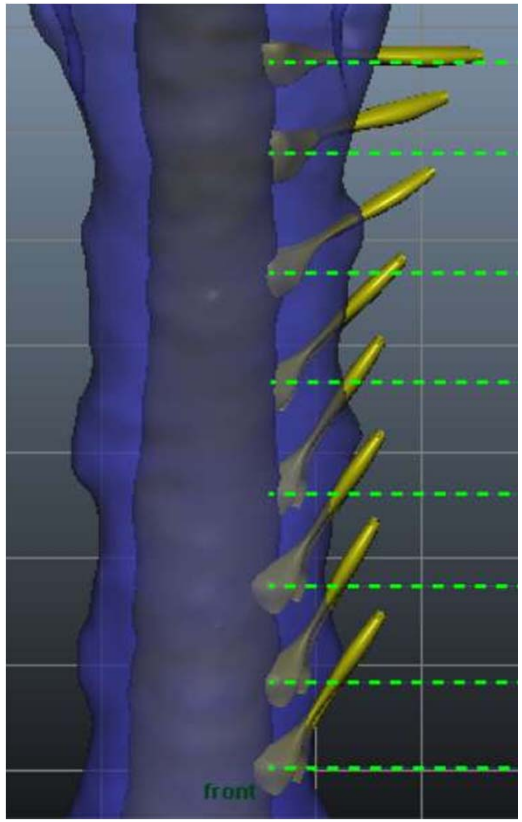

Sigmund, E. E. *et al.* High-resolution human cervical spinal cord imaging at 7 T. *NMR in biomedicine*, doi:10.1002/nbm.1809 (2011).

Test 4D MRI measurements with in vitro model

Model 1

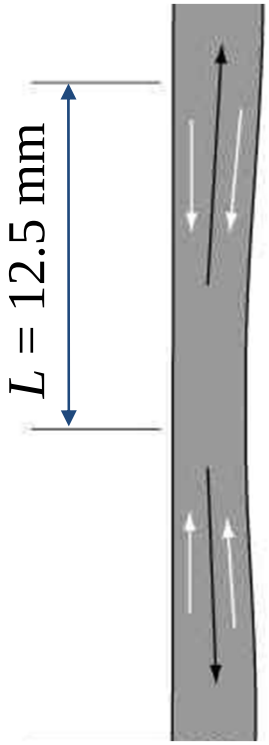

Model 2

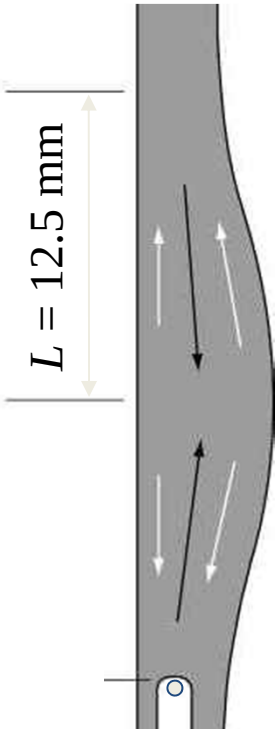



Images courtesy of Dr. Navid Borhani, EPFL thermodynamics laboratory

Conclusion

- Fine anatomy and tissue motion in the cervical spine appear to have an important impact on CSF hydrodynamics.
- To accurately model the cervical spine hydrodynamics in disease we likely need to include fine anatomy and tissue motion.
- 4D MRI is useful to understand complex flow in craniospinal disorders.


Prof. Nikos Stergiopulos
Theresia Yiallourou

EPFL neurohydrodynamics team

- Thiresia Yiallourou, EPFL, Ph.D. student
- Benedict Danny, Royal Inst., M.S. student
- Emelie Farine, M.S. student
- Anass Chiki, M.S. student
- Arthur Hirsch, EPFL, M.S. student
- Shahim Kamal, EPFL LSMX, Ph.D. student
- Serge Metarailler, EPFL, B.S. student
- Leonie Asboth, EPFL, M.S. student
- Christian Meuli, EPFL M.S. student
- Aurélie Picquot, EPFL masters student
- Adrien DeMuralt, EPFL masters student
- Navid Borhani, Ph.D.

Medical collaborators

- Jan Novy, M.D. CHUV neurology
- Lorenz Hirt, M.D., CHUV neurology
- Celine Odier, M.D. CHUV neurology
- Raphael Heinzer, M.D. CHUV sleep disorders
- Jose Haba-Rubio, M.D. CHUV sleep disorders
- Andreas Gottaschalk, M.D., Germany
- Alexander Bunck, M.D. Muenster, G.
- Shahan Momjain, M.D., HUG, Switzerland
- Bermans Iskandar, M.D. Univ. Wisc.

Work funded by:
Swiss National Science Foundation
American Syringomyelia Alliance Project
Conquer Chiari

Engineering Collaborators

- Francis Loth, Ph.D. U. Akron
- Francesco Santini, Ph.D., Uni. Basel
- Matthias Stuber, Ph.D., CHUV CIBM
- John N. Oshinski, Ph.D., Emory Univ.
- Rick Labuda, Conquer Chiari
- Jean-Marie Drezet, Ph.D., EPFL
- Jelena Bock, Ph.D., Uni. Freiburg
- Eleonora Fonari, Ph.D., CHUV CIBM
- Novak Elliott, Ph.D. Univ. Warwick
- Chris Bertram, Ph.D.

Project advise

- Carlo Marcucci, M.D. CHUV
- John D. Heiss, M.D. NIH USA
- Christopher Bertram, Ph.D.
- Lynne Bilston, Ph.D.
- Vartan Kurtcuoglu, Ph.D., ETZ, CH

Thanks!

Questions?

ÉCOLE POLYTECHNIQUE
FÉDÉRALE DE LAUSANNE